



ISSN: 0067-2904

Comparison of Some Statistical Measurements Extracted From Benign, Malignant and Normal MRI Brain Images

Raid Adnan Omar^{*1}, Jassim Mohammed Najim², Imad H Abood³

¹Department of Physics, College of Science, Anbar University, Anbar, Iraq.

²Department of Nuclear Physics, College of Science, Anbar University, Anbar, Iraq.

³Department of Statistics Physics. College of Science, Anbar University, Anbar, Iraq.

Abstract

People may believe that tissue of normal brain and brain with benign tumor have the same statistical descriptive measurements that are significantly different from the of brain with malignant tumor. Thirty brain tumor images were collected from thirty patients with different complains (10 normal brain images, 10 images with benign brain tumor and 10 images with malignant brain tumor). Pixel intensities are significantly different for all three types of images and the F-test was measured and found equal to 25.55 with p-value less than 0.0001. The means of standard deviations and coefficients of variation showed that pixel intensities from normal and benign tumors images are almost have the same behavior whereas they were significantly different from images of malignant brain tumors with F-tests equal to 23.22 and 6.51 respectively with corresponding p-values of 0.00001 and 0.005 respectively.

Keywords: Brain tumor, MRI, Mean, Filtration, Segmentation, Watershed, Pre-Processing.

مقارنة بعض القياسات الإحصائية المستخرجة من صور للدماغ ماخوذه من جهاز الرنين المغناطيسي لأشخاص يحملون امراض حميدة و اخرى خبيثة و صور لغير المرضى

رائد عدنان عمر^{*1}، جاسم محمد نجم²، عماد هجول عبود³

¹قسم علوم فيزياء، كلية العلوم، جامعة الانبار، الانبار، العراق.

²قسم الفيزياء نووية، كلية العلوم، جامعة الانبار، الانبار، العراق.

³قسم الفيزياء الاحصائي، كلية العلوم، جامعة الانبار، الانبار، العراق.

الخلاصة

قد يعتقد الناس أن نسيج الدماغ للشخص الطبيعي والنسيج للدماغ للشخص المصاب بورم حميد لديهم نفس القياسات الوصفية الإحصائية التي تختلف اختلافا كبيرا عن النسيج للدماغ لشخص مصاب بورم خبيث. جمعت ثلاثين صورة للدماغ من ثلاثين مراجعين مع اعراض مختلفة (10 صور للدماغ الطبيعي، 10 صور مع ورم في الدماغ يعد حميد و 10 صور مع ورم خبيث في الدماغ بحسب تشخيص الاطباء). اجري اختبار (F) لنتائج المتوسط الحسابي لجميع الصور و بحسب شدة البيكسل لقد اظهرت اختلافا كبيرا بين الانواع الثلاثة بحسب اختبار (F) المساوي الى 25.55 مع قيمة (p) اقل من 0.0001.

*Email: raiednan_m@yahoo.com

واظهرت نتائج الانحراف المعياري والمتوسط الحسابي فروقات بحسب تباين المتوسط الحسابي لشدة البيكسل
تبين ان صور الاورام الحميدة و صور الاشخاص الطبيعيين يوجد بينهما تقريبا فرق بسيط اي انها تسلك نفس
السلوك تقريبا في حين انها تختلف اختلافا كبيرا عن صور الاورام الخبيثة مع اختبارات (F) مساوية 23.22
و 6.21 على التوالي مع مطابقة قيم (p) نجدها 0.0001 و 0.005 على التوالي .

Introduction

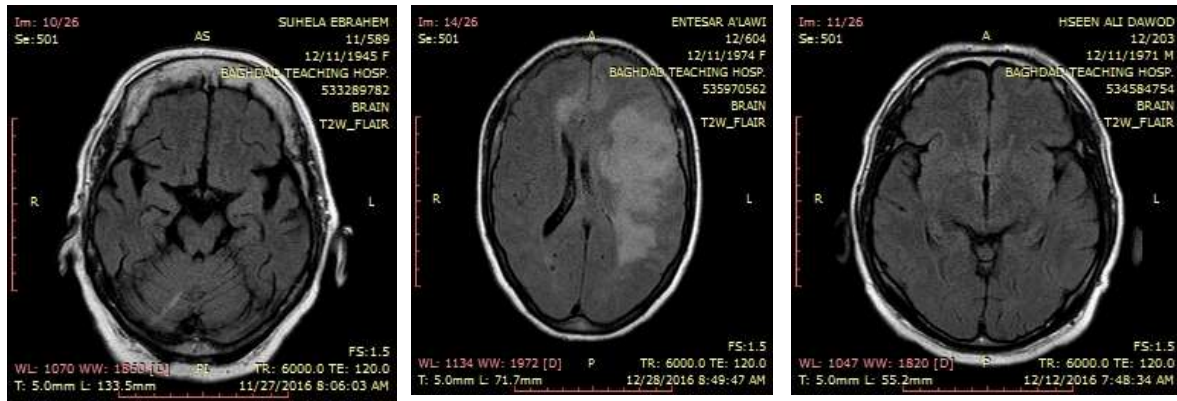
The tumor is the abnormal growth of cells and tissues. The brain tumor is an abnormal mass of cells that have grown, proliferated, uncontrollable and appear to be unchecked by the defenses that normally control normal cell growth. Tumors in the brain can be primary or metastatic and either malignant or benign[1]. Thus, these symptoms that appear in the images of the brain differ in terms of illumination and statistical distribution in terms of the natural brain and abnormal and in terms of tumor and benign and malignant. The basic principles in the research are the known techniques obtained from the MRI device and by the density of the proton and their weight in the picture T1 and T2 and are processed by the system [2]. Tissue can be describe by two different relaxation times – T1 and T2. T1 (longitudinal relaxation time) is the time constant which define the rate at which excited protons return to equilibrium. It is a measure of the time possessed for spinning protons to reorganization with the external magnetic field. T2 (transverse relaxation time) is the time constant which define the rate at which excited protons reach equilibrium or go out of phase with each other[3]. It is a measure of the time possessed for spinning protons to lose phase coherence among the nuclei spinning perpendicular to the original field. which is based on multi-spectral analysis technique[4, 5].

The beginning of pretreatment of MRI images is the basic step in image analysis that results in improved images through noise reduction techniques that are used to improve picture quality and then processes that lead to tumor size determination in the brain are applied through an algorithm that has been performed on 30 images 15 of whom were diagnosed by the reports of doctors at Baghdad Medical City Hospital as having malignant tumor, 15 patients with benign tumor, and 15 normal persons, analyzed and obtained data [6] .

Patients and methods

Images from 30 patients with different complains (10 normal brain images, 10 images with benign brain tumor and 10 images with malignant brain tumor) attended the department of MRI at the Baghdad Medical City during the period April to August 2016 were considered see Figure-1 . These thirty images were actually fall into three main categories; normal brain images, brain with benign tumor and brain with malignant tumor. All images were subjected to the following works in order to extract the necessary information regarding the undergoing research work [7]. The following scenario statements procedure were used in order to get the information needed using of MATLAB ver. R2014a [8, 9] .

1. Read image (Give MRI image of brain as input) .
2. Resize image (Resize MRI image to fit the recycling process by PCA)
3. Convert to gray scale (By used the order rgb2gray)
4. Identify threshold (Take the level of threshold to gray >80)
5. Convert to binary image (By using the order im2bw)
6. Use PCA to the converted image (by using the data in the program of DWT & PCA following the order dwt2singal and pca((name of the image))) .
7. Extract values of the determined features (by using the order mean2 and srd2 and the order mean2(var(double)) .
8. Apply the one-way analysis of variance on the extracted data. (By using (SPSS) Statistical Package for the Social software program) .



Benign

Malignant

Normal

Figure 1-MRI Scan Brain Images.

Mean and standard deviation were the main focus of this paper as they both measure the pixel intensity and its variability[10]. Both can show brief idea about how the normal or abnormal tissue can reflect the tissue ability to either pass or reflect magnetic resonance waves.

Studies that include this aspect take these statistics as a basis for their work and then proceed to a more comprehensive statistics. In this paper, the differences between the main data which lead to the following differences were examined by comparing the analysis of the intensity of the light shown in the picture in the Mean of all the images included in the building algorithm[11].

Normal tissues give structured information about the intensity of light in one pixel, while we notice the differences between the information shown on the images of people with benign diseases or malignant diseases, as well as differences between the apparent information between benign diseases on the side and malignant diseases on the other[12].

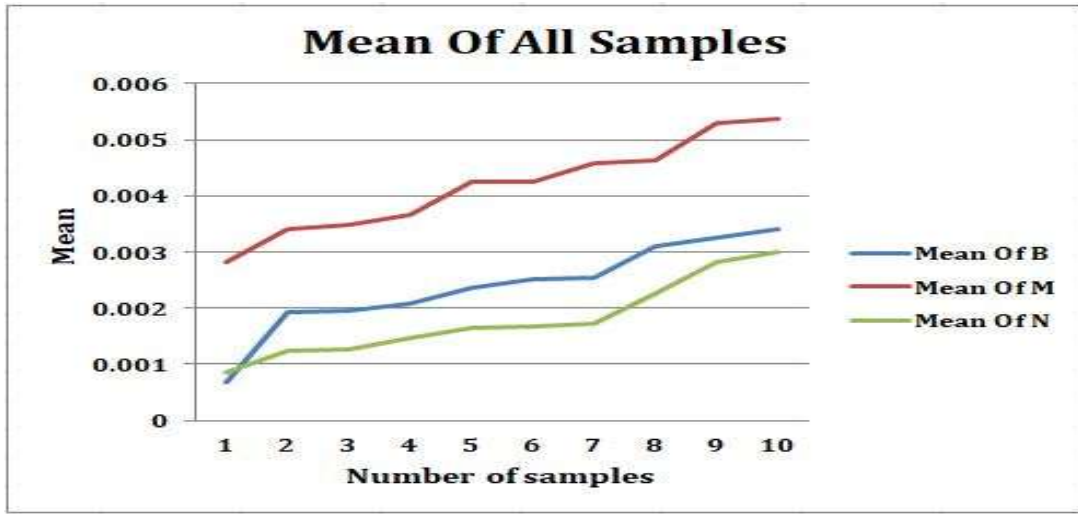
Recently, brain tumor classifications have been used through magnetic resonance imaging (MRI) and the use of basic statistical information accordingly, including mean, standard deviation and variance, and then subjecting them to filtering, classification, and segmentation of images to extract tumor location and his size [13].

Table 1- shows the extracted data from the considered images using the program written by ...

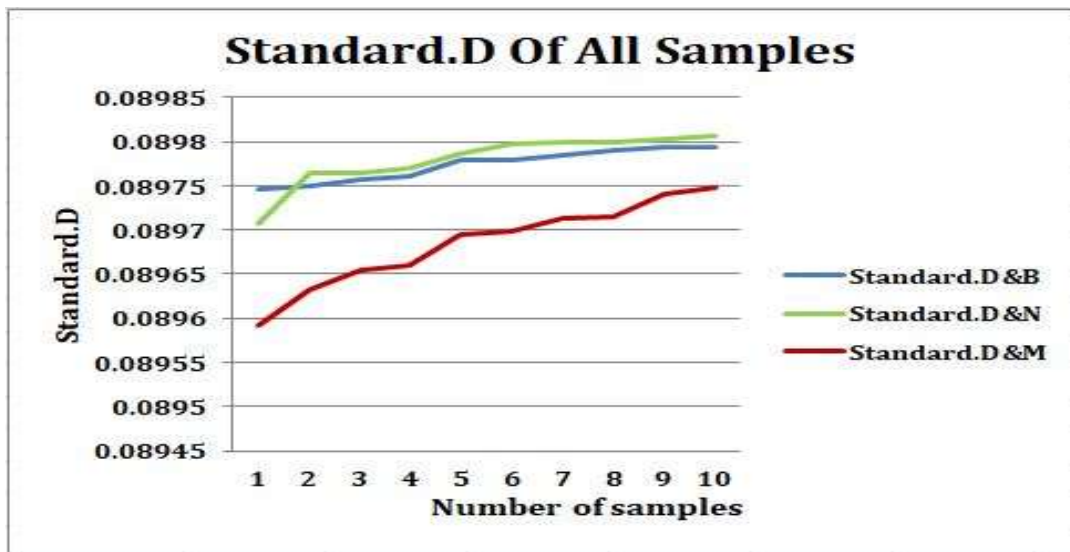
Normal Brain			Benign disease			Malignant disease		
Mean	Standard.D	Variance	Mean	Standard.D	Variance	Mean	Standard.D	Variance
0.00125412	0.089806	0.00802561	0.00068659	0.0897456	0.007987	0.00282896	0.0895928	0.007989
0.00224999	0.0897865	0.0080299	0.0019318	0.0897499	0.008019	0.00341361	0.0896327	0.008018
0.00164282	0.0897997	0.00802435	0.00193931	0.0897562	0.008027	0.00348476	0.0896542	0.008018
0.00172607	0.0897981	0.00803095	0.0020681	0.0897608	0.00803	0.00365066	0.0896592	0.008031
0.00167344	0.0897991	0.00802756	0.00235179	0.089779	0.008048	0.00423595	0.0896947	0.008036
0.00300133	0.0897645	0.00802883	0.00250954	0.0897796	0.008051	0.00425992	0.0896977	0.008036
0.00438094	0.0897078	0.00802589	0.00253273	0.0897839	0.008052	0.00458293	0.0897136	0.008047
0.00146406	0.0898028	0.00803316	0.0031107	0.0897909	0.008052	0.00464175	0.0897148	0.00805
0.0028178	0.0897705	0.00803582	0.0032427	0.0897938	0.008056	0.00528247	0.0897405	0.008054
0.00122761	0.0898063	0.00803054	0.00341193	0.0897939	0.008063	0.00536637	0.0897471	0.008057

Results

Figures-2 (a, b) showed the variability of the means and standard deviations of the considered patients. Obviously, tissues of normal and benign brain tumor have approximately the same ability to react to MR waves, whereas tissues of malignant brain tumor have remarkably higher ability to react to MR waves.



(A)



(B)

Figure 2(A, B)- The variability of the means and standard deviations of images.

One-Way Analysis of Variance

Analysis of Variance for Means

Source	DF	SS	MS	F	P
C4	2	0.0000309	0.0000154	25.55	0.000
Error	27	0.0000163	0.0000006		
Total	29	0.0000472			

Individual 95% CIs For Mean

Based on Pooled StDev

Level	N	Mean	StDev	-----+-----+-----+-----
Normal	10	1.79E-03	6.98E-04	(----*----)
Benign	10	2.38E-03	7.99E-04	(----*----)

Tissue from benign brain tumors although it is not significantly different from that of normal brain tissue, but still indicate the fact that such tissue may develop malignancy if not handled carefully. The results showed that the three types of images are normal, benign and malignant. The differences between the three types are distinguished by the statistical information obtained from the images.

Diagnosis of the doctor deliberately to see the theoretical comparison between images in the memory of the memory stored in the brain, which may have a certain error rate, the intensity of light in one pixel and the comparison between them and the images give greater accuracy and thus can be used these processes that do not complicate complex to ascertain the validity of the diagnosis in addition to possible consideration of the condition of the patient in terms of response to treatment compared to the statistical information for the pre- and after taking the therapeutic dose.

References

1. Bailey, D. L., Humm, J. L., Todd-Pokropek, A. and Aswegen, A. V. **2014**. *Nuclear Medicine Physics*: American Association of Physicists in Medicine (AAPM), Asia–Oceania Federation of Organizations for Medical Physics (AFOMP), Australasian College of Physical Scientists and Engineers in Medicine (ACPSEM), European Federation of Organisations for Medical Physics (EFOMP), Federation of African Medical Physics Organisations (FAMPO), World Federation of Nuclear Medicine and Biology (WFNMB).
2. Mohsin, S. A., Sheikh, N. M. and Saeed, U. **2008**. MRI induced heating of deep brain stimulation leads: Effect of the air-tissue interface. *Progress In Electromagnetics Research*, **83**: 81-91.
3. Gonzalez, W. **2008**. *Digital Image Processing*: 2nd ed. Prentice Hall. 378.
4. Zhang, Y., and Wu, L. **2012**. An MR brain images classifier via principal component analysis and kernel support vector machine. *Progress in Electromagnetics Research*, **130**: 369-388.
5. Patil, R. C. and Bhalchandra, A. S. **2012**. Brain tumour extraction from MRI images using MATLAB. *International Journal of Electronics, Communication and Soft Computing Science & Engineering (IJECSCE)*, **2**(1): 1.
6. Zhang, Y., Wu, L. and Wang, S. **2011**. Magnetic resonance brain image classification by an improved artificial bee colony algorithm. *Progress in Electromagnetics Research*, **116**: 65-79.
7. Tagluk, M. E., Akin, M., and Sezgin, N. **2010**. Classification of sleep apnea by using wavelet transform and artificial neural networks. *Expert Systems with Applications*, **37**(2): 1600-1607.
8. Zhang, Y., Wu, L., and Wei, G. **2009**. A new classifier for polarimetric SAR images. *Progress In Electromagnetics Research*, **94**: 83-104.
9. Cocosco, C. A., Zijdenbos, A. P. and Evans, A. C. **2003**. A fully automatic and robust brain MRI tissue classification method. *Medical image analysis*, **7**(4): 513-527.
10. Wilks, D. S. **2011**. *Statistical methods in the atmospheric sciences* (Vol. 100). Academic press.
11. Avula, M., Lakkakula, N. P., and Raja, M. P. **2014**. Bone Cancer Detection from MRI Scan Imagery Using Mean Pixel Intensity. In *Modelling Symposium (AMS), 2014 8th Asia* (pp. 141-146). IEEE.
12. Nguyen, T. L., Choi, Y. H., Aung, Y. K., Evans, C. F., Trinh, N. H., Li, S., ... and Sung, J. **2017**. Breast Cancer Risk Associations with Digital Mammographic Density by Pixel Brightness Threshold and Mammographic System. *Radiology*, 170306.
13. Sehgal, A., Goel, S., Mangipudi, P., Mehra, A., and Tyagi, D. **2016**. Automatic brain tumor segmentation and extraction in MR images. In *Advances in Signal Processing (CASP), Conference on* (pp. 104-107). IEEE.
14. Kueh, H. Y., Marco, E., Springer, M. and Sivaramakrishnan, S. **2008**. *Image analysis for biology*. MBL Physiology Course 2008.
15. Parvathi, K. S., Tawde, R. and Shah, S. **2013**. Extraction of tumor and cancer cells of brain MRI images by using different morphological operations. *International Journal of Emerging Trends in Electrical and Electronics*, **4**(1).