




Punicalagin protects against the development of pancreatic injury and insulinitis in rats with induced T1DM by reducing inflammation and oxidative stress

Haitham L. Abdulhadi¹ · Banan R. Dabdoub² · Loay H. Ali¹ · Azza I. Othman³ · Maggie E. Amer³ · Mohamed A. El-Missiry³ 

Received: 10 February 2022 / Accepted: 13 May 2022

© The Author(s), under exclusive licence to Springer Science+Business Media, LLC, part of Springer Nature 2022

Abstract

Pancreatic inflammation and oxidative damage remain major concerns in type 1 diabetes mellitus (T1DM). Punicalagin, a major polyphenol in pomegranates, exhibited antioxidant and protective effects on several organs in case of T1DM; however, no study has yet explored the protective effects of punicalagin on the pancreas and islets of Langerhans. T1DM was induced by injecting 40 mg/kg streptozotocin (STZ) intraperitoneally. Punicalagin (1 mg/kg ip) was injected daily for 15 days after T1DM induction. In diabetic rats, punicalagin treatment lowered the levels of inflammatory biomarkers (monocyte chemoattractant protein-1 and C-reactive protein) and adhesion molecules (E-selectin, intercellular adhesion molecule, and vascular cell adhesion molecule) while activating myeloperoxidase activity. Treatment of diabetic rats with punicalagin improved glutathione content and superoxide dismutase, catalase, and glutathione peroxidase activities; upregulated serum paraoxonase-1 activity; and prevented the elevation lipid peroxidation and protein oxidation products in the pancreas. Furthermore, punicalagin protected the pancreas against STZ-induced histopathological alterations and increased immune-reactive β -cells while reducing leucocyte infiltration into the islets of Langerhans, leading to normalized blood glucose and insulin levels. These findings indicated that punicalagin might protect against the development of insulinitis in T1DM. In conclusion, punicalagin exerts a strong protective effect on the pancreas against oxidative injury and inflammation in STZ-induced experimental T1DM. The present results recommend punicalagin as a potential adjuvant for reducing diabetes-associated insulinitis.

Keywords Pancreas · Punicalagin · Antioxidants · C-reactive protein · Myeloperoxidase · Paraoxonase-1 · Oxidative stress · ICAM-1 · VCAM-1

Introduction

Type 1 diabetes mellitus (T1DM) is a chronic autoimmune disease characterized by remarkable damage to the β -cells of the islets of Langerhans, leading to low insulin release and

augmented hyperglycemia [1]. Pancreatic cell injury occurs as a result of increased oxidative stress and inflammation [2]. The pathological hallmark of T1DM is the development of insulinitis, which characterized by inflammation due to immune cell infiltration into the islets of Langerhans causing the selective loss of β -cells [3]. Therefore, it is important to search for therapeutic agents with minimal side effects to protect the pancreas and β -cells against oxidative stress and inflammatory response associated with T1DM.

Nutraceuticals, such as polyphenols, are antioxidant compounds found in several colored fruits, vegetables, and herbs. These compounds have shown several beneficial effects in health and diseases, including diabetes [4]. Moreover, they have various biological functions, such as immunomodulation, anti-inflammation, and antioxidation [5]. One popular fruit is pomegranate, with recent studies showing that

✉ Maggie E. Amer
maggieelsied@mans.edu.eg

✉ Mohamed A. El-Missiry
elmissiry@mans.edu.eg; maelmissiry@yahoo.com

¹ Biology Department, College of Education for Pure Sciences, University of Anbar, Anbar, Ramadi, Iraq

² Biology Department, College of Education for Pure Sciences, University of Mosul, Mosul, Iraq

³ Zoology Department, Faculty of Science, Mansoura University, Mansoura, Egypt

pomegranate extract promoted protective effects against hepatic damage in case of T1DM [6].

Punicalagin is a polyphenol found mainly in pomegranate juice, peel, and seeds. It is the major phenolic compound found in pomegranate peels [7, 8]. Punicalagin is characterized by its remarkable antioxidant and free radical scavenging activity among other polyphenol-rich plants [9] and exerts several health benefits [10]. Evidence has shown that punicalagin can protect the heart against oxidative injury produced by ischemia/reperfusion [11] and T1DM [12]. Moreover, studies have showed that punicalagin protected against diabetic nephropathy [13] and mitigated the teratogenic effects of hyperglycemia in the developing embryo [14]. Recently, punicalagin showed therapeutic effects on multiple targets, consequently ameliorating metabolic syndrome [15]. However, the effects of punicalagin on pancreatic integrity, as well as the islets of Langerhans and its β -cells, in T1DM have yet to be explored. We hypothesized that punicalagin treatment can be a promising approach for protecting the pancreas and insulin-secreting cells against streptozotocin (STZ)-induced damage. The current study therefore aimed to investigate the protective effects of punicalagin against pancreatic injury in experimental diabetic rats.

Materials and methods

Inducing diabetes and treatment with punicalagin

To induce T1DM, rats were injected with a single dose of STZ (40 mg/kg, intraperitoneally) after overnight fasting [16]. STZ was obtained from Sigma-Aldrich Co., USA and prepared in citrate buffer (pH 4.5) [17]. Blood glucose levels

were estimated to verify hyperglycemia. Rats with blood glucose levels over 250 mg/dL were confirmed to have diabetes and were utilized in the current study.

Punicalagin supplied by Sigma-Aldrich, USA was prepared in saline solution and administered intraperitoneally at a concentration of 1 mg/kg daily for 15 days [12].

Experimentation animals and design

Adult male Westar rats weighing 250 ± 20 g were supplied by VACSERA (Giza, Egypt). They were kept under controlled humidity, temperature, and photoperiod (12-h light/dark cycle). Rats were fed a commercial rodent pellet diet and water ad libitum. Animals were acclimatized to the place and then randomly divided into the following four groups of six animals each: (1) Control group: rats that did not receive any treatment; (2) punicalagin (PU) group: rats that received a intraperitoneal injection of punicalagin (1 mg/kg body weight, intraperitoneally) for 15 days; (3) streptozotocin (STZ) group: rats were injected intraperitoneally with streptozotocin (40 mg/kg, intraperitoneally) [18]; and (4) streptozotocin + punicalagin (STZ + PU) group: rats that received STZ followed by punicalagin at the same dose as the second and third groups for 15 days (Fig. 1).

Sample collection

After the experimental period, rats were anesthetized with ketamine/xylazine (0.1 ml/100 g, intraperitoneally). Blood was obtained from the heart by cardiac puncture under anesthesia, after which the animals were dissected to obtain the pancreases. After blood clotting, sera were obtained by centrifugation at 3000 rpm for 10 min and stored at -20 °C. A portion of the pancreas was

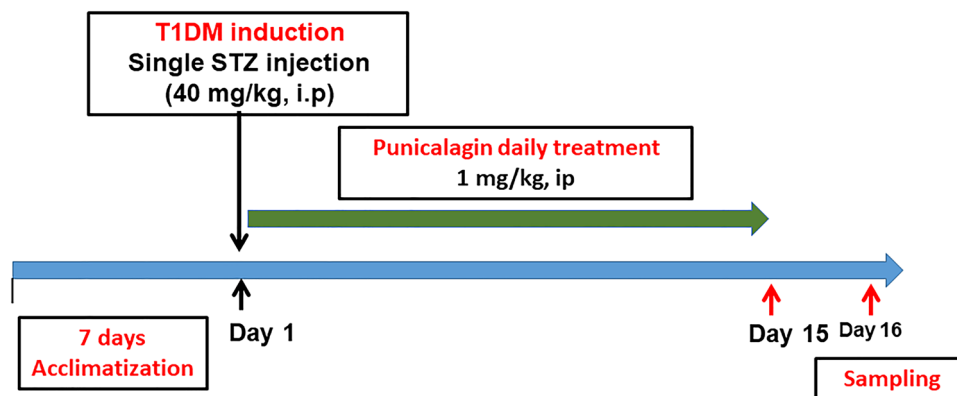


Fig. 1 Experimental design. In the current study, four animal groups were used to investigate potential therapeutic effect of punicalagin in pancreatic injury and insulinitis in STZ-induced diabetic model. Animals were acclimatized for seven days before experimentation. The experimental groups are as follows: (1) control group; (2) punicalagin

(PU) group; (1 mg/kg body weight, ip for 15 days); (3) streptozotocin (STZ) group: (40 mg/kg, ip); and (4) streptozotocin + punicalagin (STZ + PU) group: rats that received STZ followed by punicalagin at the same dose as the second and third groups for 15 days. Animals were overnight fasted then samples were collected next day

homogenized, centrifuged, and then stored at -20°C . For histological and immunohistochemical studies, portions of the pancreas were fixed in 10% neutral formalin until processing.

Biochemical determinations

The levels of serum glucose were evaluated using ready-made kits (Glucose-LQ) provided by Spinreact (Girona, Spain). The levels of serum insulin were assayed using the ELISA kit (RayBiotech, Georgia, USA; Catalog #: ELR-Insulin-1) with a detection range of 5–300 uIU/mL, respectively.

Serum C-reactive protein (CRP) and Paraoxonase-1 (PON-1) activity were assessed using ELISA kits provided by MyBiosource (San Diego, USA) according to the instruction manual (Catalog# MBS453159) and (Catalog# MBS453155).

Serum levels of attaching molecules, including blood vessel endothelial adhesion molecule-1 (VCAM-1) (Catalog# A01199) and intracellular adhesion molecule-1 (ICAM-1) (Catalog# EK0372), were measured using a commercial ELISA kit (Boster Biological Technology, Pleasanton CA, USA). E-selectin was detected using ELISA kit supplied from Thermo Fisher Scientific, USA, (Catalog# ERA14RB) according to the manufacturer's instructions. Serum MCP-1 levels were determined using an ELISA (RayBiotech, USA, (Catalog# ELR-MCP-1-1)).

Glutathione (GSH) levels in pancreatic tissues and the activities of glutathione reductase (GR), (GPx), (SOD), and (CAT) were determined using the kits provided by MyBiosource (San Diego, USA) according to the instruction manual (Catalog# MBS258033), (Catalog# MBS841852), (Catalog# MBS1600242), (Catalog# MBS036924), and (Catalog# MBS726781), respectively.

Furthermore, myeloperoxidase (MPO) activity, protein carbonyl (PC), and malondialdehyde (MDA) were estimated in the pancreas following the instructions of the kit obtained from MyBiosource San Diego, USA, (Catalog# MBS849288), (Catalog# MBS2600784), and (Catalog# MBS268427), respectively.

Histopathological investigation

Fixed pancreatic tissues from all rat groups were dehydrated in graded ethanol concentrations and then cleaned with xylene after being washed with 70% alcohol. The samples were mounted in wax, sectioned at 6 μm , and stained with hematoxylin and eosin. Stained sections were observed using an Olympus light microscope and photographed using an Amscope MU1000 camera. Furthermore, the degree

of insulinitis was quantified using image analysis, based on the degree of leucocyte infiltration and % of plot area.

Immunohistochemical study

Insulin expression was determined in paraffin-embedded sections using the labeled streptavidin–biotin immunoperoxidase technique [19]. Pancreas sections were deparaffinized in xylene and rehydrated in alcohol, after which they were incubated overnight at 4°C with mouse monoclonal anti-insulin (Cat #: insulin Ab-5 (Clone INS05; same as 2D11-H5), Thermo Fisher Scientific, Fremont, CA; diluted 0.5–1 $\mu\text{g}/\text{ml}$). After completing the reaction, counterstaining was performed using Mayer's hematoxylin, and the sections were dehydrated and cover slipped using DPX. The β -cell area ratio was quantified as the area of insulin-positive cells divided by the total tissue area using ImageJ 1.42q software [20]. At least six random islets from each section were counted for insulin-positive areas.

Statistical analysis

Using GraphPad Prism version 6.01, the results were expressed as means and standard error of mean (\pm SEM). Student's t test was utilized to determine statistical differences between two groups, whereas one-way analysis of variance followed by Tukey's test was used for multiple comparisons. A P value of <0.05 was considered statistically significant.

Results

Punicalagin reduced serum inflammatory mediators in T1DM rat model

Diabetic rats had significantly higher CRP and MCP-1 levels and MPO activity ($P < 0.001$) than the control group. Moreover, diabetic rats treated with punicalagin exhibited markedly lower levels of the aforementioned inflammatory bioindicators compared to the diabetic group (Fig. 1). Compared to the control group, rats with STZ-induced T1DM treated with punicalagin showed no significant difference in the level's inflammatory markers. Treatment with punicalagin alone displayed no significant effects on CRP and MCP-1 levels (Fig. 2A and B) and promoted no significant decrease ($P < 0.05$) in serum MPO activity (Fig. 2C) compared to the control rats (Fig. 2).

Punicalagin suppressed the release of adhesion molecules in sera of diabetic rats

Similarly, the STZ-injected group had a significant greater ($P < 0.001$) serum concentrations of ICAM-1, VCAM-1,

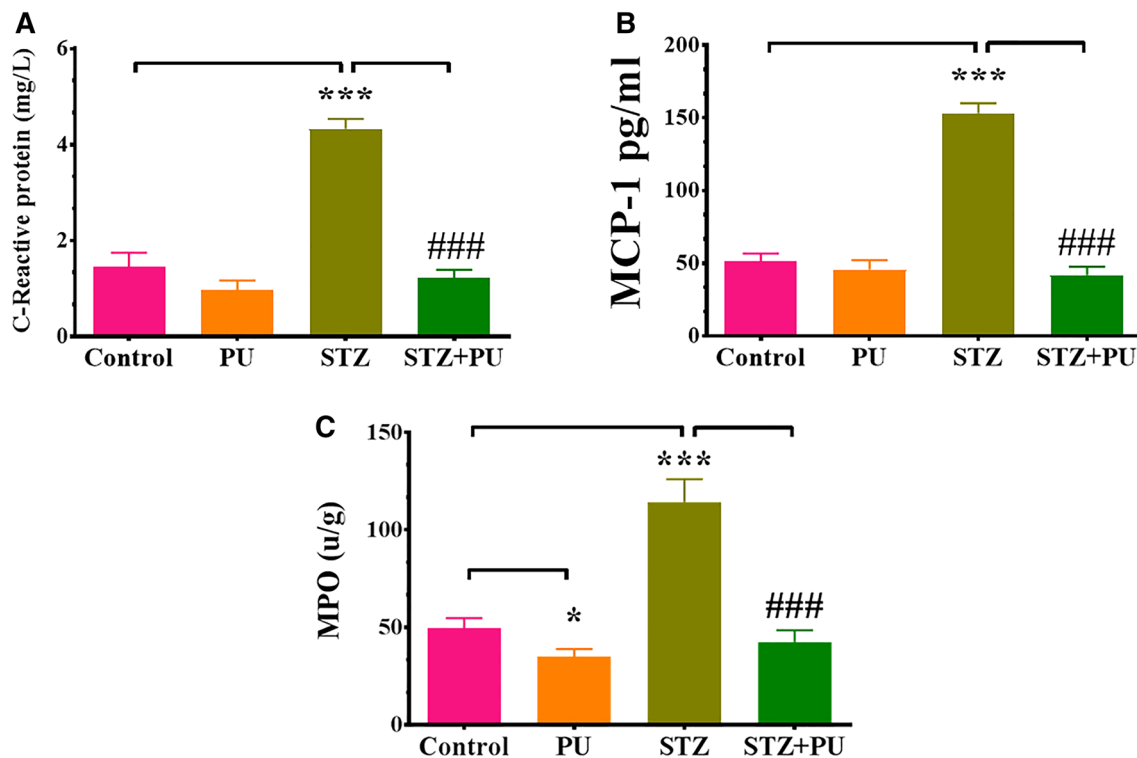


Fig. 2 A–C Effects of streptozotocin (STZ) and punicalagin (PU) on serum levels of C-reactive protein (CRP) (A), monocyte chemoattractant protein-1(MCP-1) (B) and myeloperoxidase (MPO) (C) activity in pancreatic tissues of rats in the different groups. Values are

expressed as the means \pm SEM; ($n=6$). *Significant at $P<0.05$. ***, ### Significant at $P<0.001$. * ,*** Indicate comparisons with respect to the control group. ### Indicates comparisons with respect to the STZ group

and E-selectin compared to the control group (Fig. 3A–C, respectively). By contrast, diabetic rats treated with punicalagin had a significantly lower concentrations of ICAM-1, VCAM-1, and E-selectin ($P<0.001$) compared to the STZ-treated group. Treatment with punicalagin alone did not affect the expression of adhesion molecules in sera (Fig. 3).

Punicalagin reduced oxidative stress and increased antioxidant levels in the pancreas of diabetic rats

Compared to the control, treatment with punicalagin for 15 days caused a significant increase in antioxidant level in the pancreas ($P<0.001$). In contrast, diabetic rats exhibited a significant decrease in GSH levels ($P<0.001$) and activities of GPx, GR, SOD, and CAT in the pancreas and of PON-1 in sera (Fig. 4A–F, respectively). Diabetic rats treated with punicalagin showed significant greater antioxidant levels compared with the diabetic group (Fig. 4).

Furthermore, diabetic rats exhibited a significant protein oxidation and lipid peroxidation ($P<0.001$) as indicated by higher levels of protein carbonyl (PC) and malondialdehyde (MDA) in the pancreas compared with control animals (Fig. 5A and B). Diabetic rats treated with punicalagin had significantly lower protein oxidation and lipid peroxidation

compared to diabetic rats (Fig. 5). Punicalagin treatment in rats with STZ-induced T1DM showed no significant effect on PC and MDA formation in the pancreas.

Punicalagin mitigated histopathological alterations in the pancreas and prevented insulinitis of T1DM rats

Pancreatic tissues from the control and punicalagin groups showed normal histological architecture of both the exocrine and endocrine glands as indicated by the normal appearance of the islets of Langerhans surrounded by exocrine pancreatic acinar structures. In rats with STZ-induced diabetes, degenerative and necrotic changes within the exocrine glands and marked decrease in the size of the endocrine islets of Langerhans were consistently observed. By contrast, pancreatic tissues from the STZ+PU group showed amelioration of these histopathological alterations in majority of the islets of Langerhans cells, with mild degenerative changes within exocrine glands (Fig. 6A–D and Fig. S1).

The effects of punicalagin on the severity of insulinitis in diabetic rats was quantified using image analysis, based on the degree of leucocyte infiltration (Fig. 6E) and plotted area (Fig. 6F). Compared with the control rats, rats with STZ-induced diabetes had significantly greater leukocytes

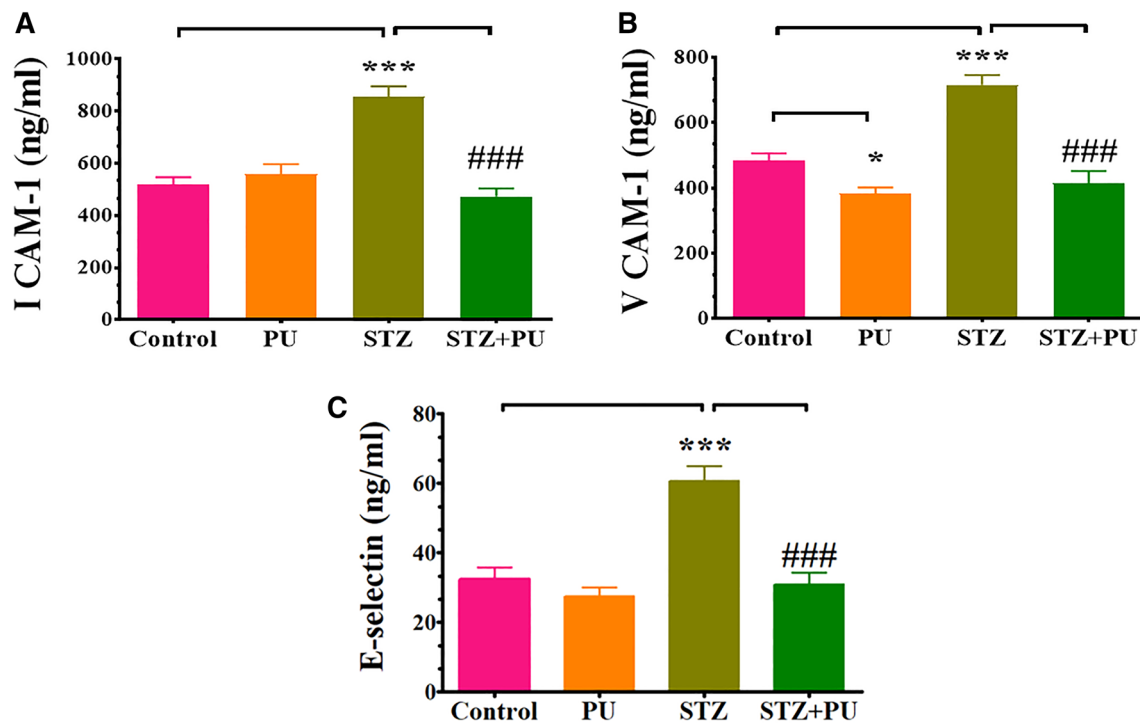


Fig. 3 A–C Effects of streptozotocin (STZ) and punicalagin (PU) on serum level of adhesion molecules, namely intracellular adhesion molecule-1 (ICAM-1) (A), vascular endothelial adhesion molecule-1 (VCAM-1) (B), and E-selectin (C), in rats of different groups. Values

are expressed as mean ± SEM; (n=6). * Significant at $P < 0.05$. ***, ### Significant at $P < 0.001$. ***, ### Indicate comparisons with respect to the control group. ### Indicate comparisons with respect to the STZ group

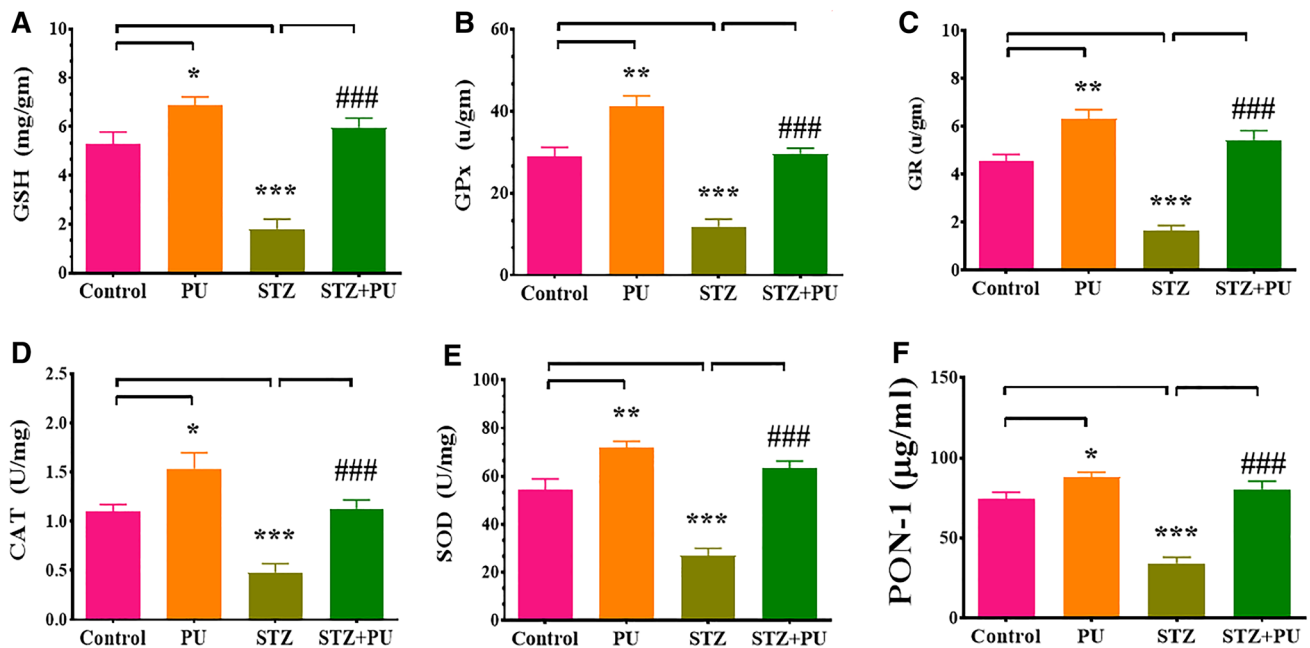


Fig. 4 A–F Effects of streptozotocin (STZ) and punicalagin (PU) on antioxidant activities of glutathione (GSH) (A), glutathione peroxidase (GPx) (B), glutathione reductase (GR) (C), catalase (CAT) (D), and superoxide dismutase (SOD) (E) in the pancreas and parotid gland (PON-1) (F) serum levels in rats of different groups. Values are

expressed as mean ± SEM; (n=6). *Significant at $P < 0.05$; ** Significant at $P < 0.01$, and ***, ### Significant at $P < 0.001$. *, **, *** Indicate comparisons with respect to the control group. ### Indicates comparisons with respect to the STZ group

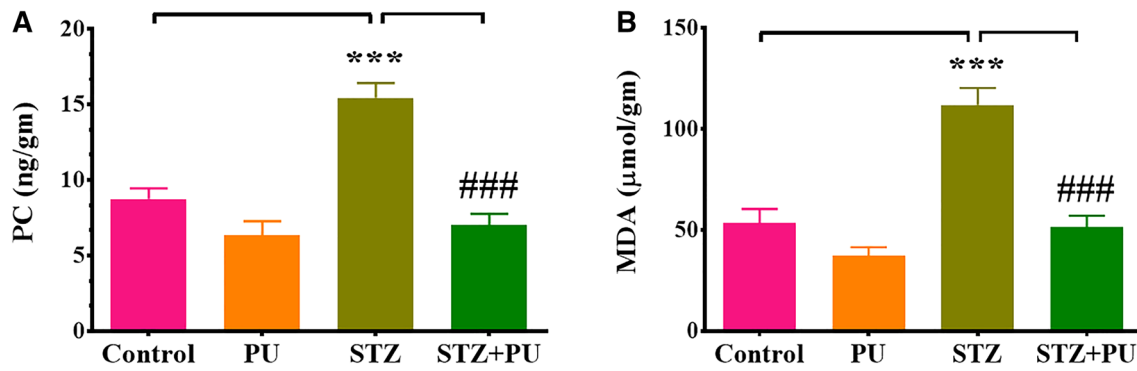


Fig. 5 A–B Effects of streptozotocin (STZ) and punicalagin (PU) on the levels of protein carbonyl (PC) (A) and malondialdehyde (MDA) (B) in the pancreas of rats in different groups. Values are expressed as

mean \pm SEM; ($n=6$). ***, ### Significant at $P<0.001$. *** Indicates comparisons with respect to the control group. ### Indicates comparisons with respect to the STZ group

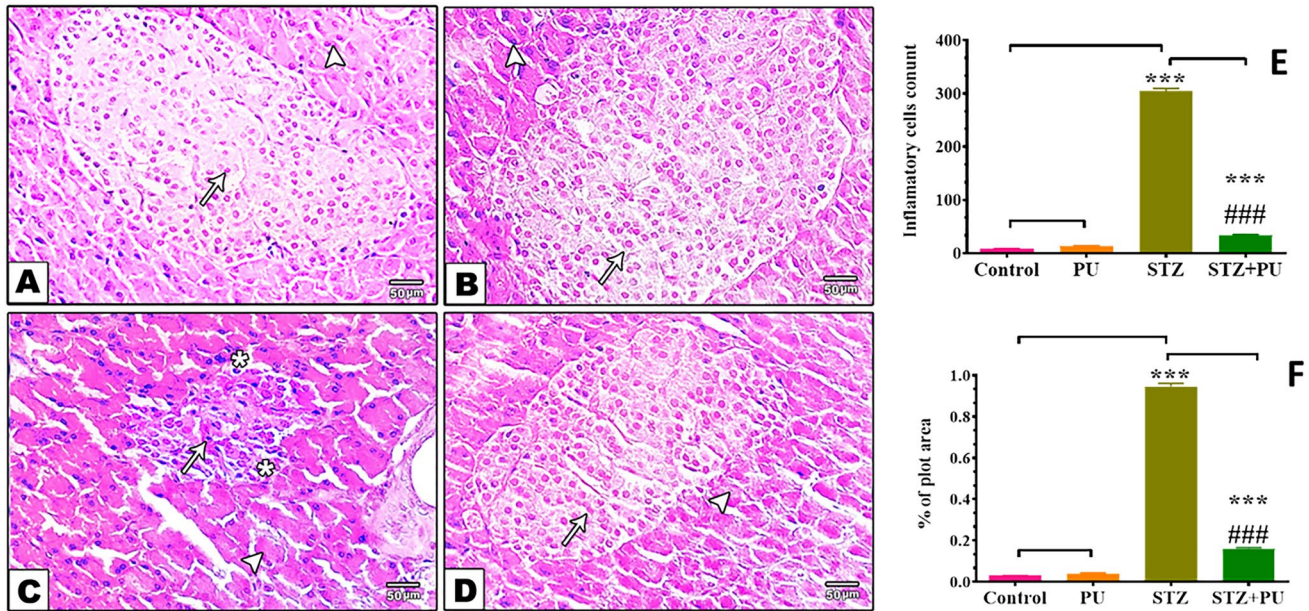


Fig. 6 A–D Hematoxylin and eosin-stained pancreatic sections. **A** Control rats showing normal histological features of both exocrine and endocrine structures, (arrowhead) indicating normal acinar structures and (arrow) indicates islets of Langerhans. **B** Section of punicalagin (PU)-treated animal, showing normal histological features of both exocrine and endocrine tissues, (arrowhead) indicating normal acinar structures and (arrow) islets of Langerhans. **C** Section from rats with streptozotocin-(STZ) induced diabetes showing marked decrease in size of the endocrine islets of Langerhans with a drastic decrease in the number of their cells (arrow). Some islet cells are distorted with vacuolated cytoplasm (asterisk); degenerative changes

within exocrine pancreatic acini (arrowhead). **D** Section of streptozotocin + punicalagin-treated (STZ + PU) animals showing an apparent increase in the islets of Langerhans size with normal histoarchitecture (arrow) in addition to exocrine pancreatic acini appearing with almost normal histology (arrowhead) (Magnification: $\times 200$). Quantification is expressed as inflammatory cell count and percent of plot area (E and F, respectively). Each value represents mean \pm SEM of six microscopic fields/tissue sample. ***, ### Significant at $P<0.001$. *** Indicates comparisons with respect to the control group. ### Indicates comparisons with respect to the STZ group

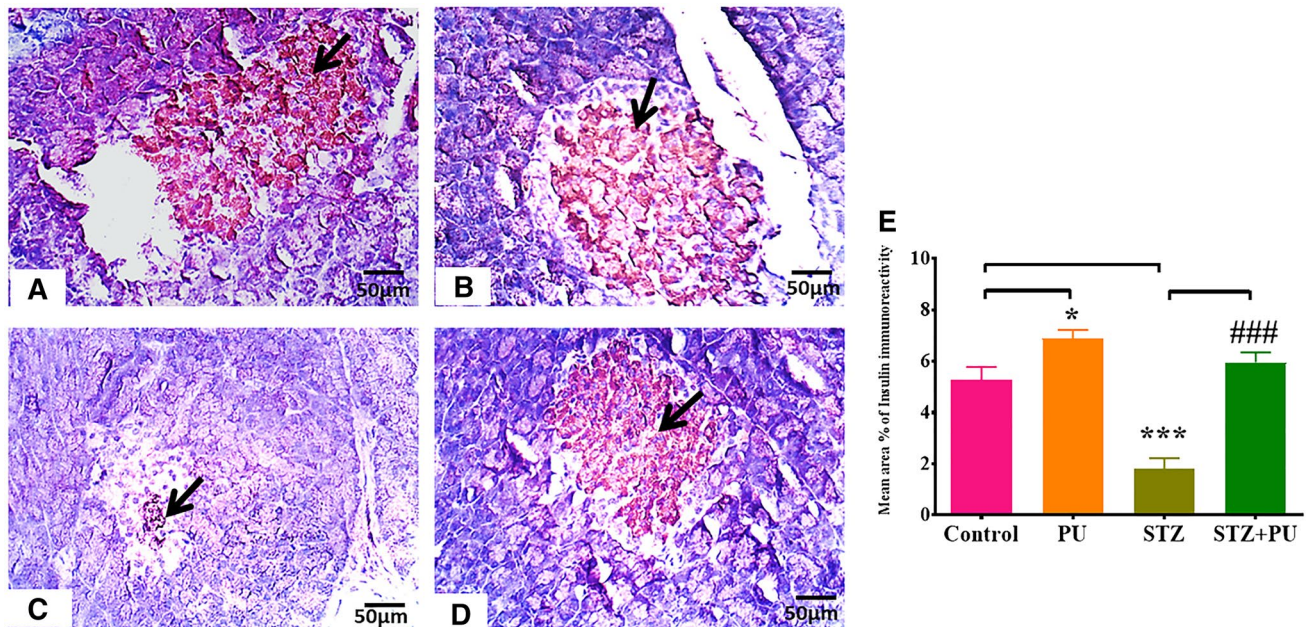


Fig. 7 A–E Pancreatic-stained sections with insulin antibody. **A** Control group showing strongly stained β -cells of the islet of Langerhans with the anti-insulin antibody (arrow); **B** punicalagin (PU)-treated group showing β -cells in the islet of Langerhans that are strongly stained with the anti-insulin antibody (arrow); **C** rats with streptozotocin-(STZ) induced diabetic showing weak insulin immunoreactivity in a few β -cells in the islet of Langerhans (arrow); and **D** streptozotocin + punicalagin-treated (STZ+PU) group, PU protected the

majority of β -cells in the islet of Langerhans and strongly stained them with the anti-insulin antibody (arrow). (IHC, X200). The effect of streptozotocin (STZ) and punicalagin (PU) on the percentage of insulin-positive cells in pancreatic islets of different groups (E) was quantified. Each value represents the mean \pm SE of six microscopic fields/tissue sample. *Significant at $P < 0.05$. ***, ### Significant at $P < 0.001$. ***, * Indicate comparisons with respect to the control group. ### Indicate comparisons with respect to the STZ group

infiltration ($P < 0.001$). In contrast, treatment of diabetic rats with punicalagin significantly reduced leukocyte infiltration into the islets of Langerhans (Fig. 6E and F). These findings indicated that punicalagin mitigated T1DM-associated insulinitis.

Punicalagin protected β -cells in the pancreas of T1DM rats

Pancreatic sections of normal rats showed strong insulin immunoreactivity in the β -cells of the islets of Langerhans. Interestingly, pancreatic sections of punicalagin-treated rats displayed a more insulin-immunopositive cells ($P < 0.05$) compared to the control group (Fig. 7A and B). The STZ group showed remarkably low immunoreactivity staining intensity in the insulin-secreting cell population, indicating destruction of β -cells (Fig. 7C). In contrast, the STZ+PU group showed an apparently greater increase in the number and size of reactive β -cells compared with the STZ group (Fig. 7D). The quantification of insulin-immunopositive cells is illustrated in Fig. 7E.

Punicalagin ameliorated serum glucose and insulin levels in T1DM rats

Figure 7 shows the levels of glucose and insulin in sera. Compared with the control group, rats with STZ-induced T1DM treated with punicalagin showed no significant difference in serum glucose and insulin levels. In contrast, injection of STZ caused a significant increase in serum glucose and decrease in insulin levels ($P < 0.001$). Meanwhile, treatment of diabetic rats with punicalagin significantly prevented these changes in both biomarkers ($P < 0.001$) (Fig. 8A and B).

Discussion

T1DM is an autoimmune disease characterized by damage of pancreatic β -cells due to excessive immune cell infiltration into the islets of Langerhans [21, 22]. The present study planned to assess the role of punicalagin in protecting the pancreas of rats with STZ-induced diabetes. This has been the first study to show that punicalagin exerts anti-insulinitis effects and protects the pancreas against oxidative damage in T1DM rats. Treatment with punicalagin protected the

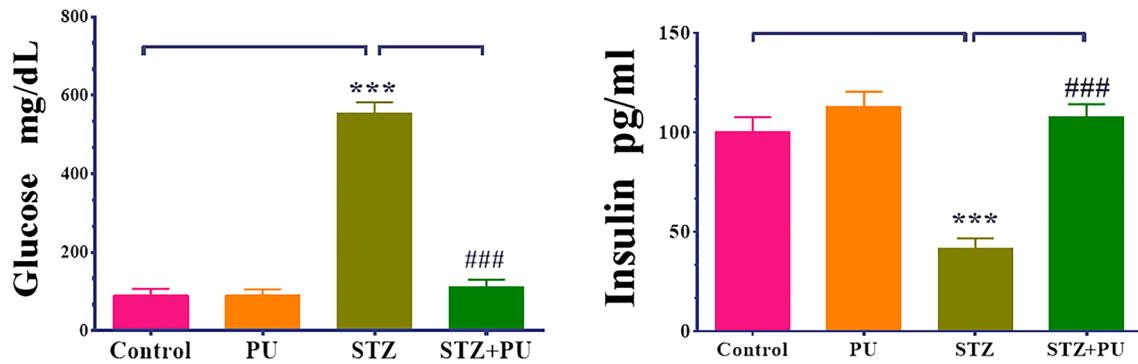


Fig. 8 Effect of streptozotocin (STZ) and punicalagin (PU) on the levels of glucose and insulin in the sera of rats in different groups. Values are expressed as mean \pm SEM; ($n=6$). ***, ### Significant

at $P < 0.001$. *** Indicates comparisons with respect to the control group. ### Indicates comparisons with respect to the STZ group

pancreas against STZ-induced increase in oxidative stress, inflammatory attack, histological alterations, and reduced leucocyte infiltration into the islets of Langerhans, leading to the normalization of blood glucose and insulin levels.

The current study and a previous report showed that STZ causes pancreatic inflammation with concomitant increases in pro-inflammatory cytokines and mediators [23]. Serum CRP levels, together with other inflammatory cytokines and soluble adhesion molecule, become elevated in T1DM patients [24]. The current study demonstrated that punicalagin administration decreased the levels of pro-inflammatory cytokines CRP and MCP-1 in sera and reduced MPO activity in the pancreas of rats with STZ-induced diabetes, confirming the anti-inflammatory effects of punicalagin. This finding agrees with a previous report, which suggested that diabetic mice have higher plasma MCP-1 levels and that inhibiting this molecule helps reduce insulinitis [25]. When punicalagin was administered to diabetic rats, the serum levels of CRP and MCP-1 improved significantly with increased MPO activity. This finding is consistent with those of previous studies, which showed that punicalagin attenuated inflammatory responses through the downregulation of the FoxO3a/autophagy signaling pathway, nitric oxide, prostaglandin E2, interleukin-6, and cyclooxygenase-2 (COX-2) release in several conditions [26–28]. This finding suggests that punicalagin is crucial in reducing inflammation by minimizing CRP and MCP-1 production and activation of MPO, supporting the anti-inflammatory effects of punicalagin.

Furthermore, diabetic rats had high concentrations of cell adhesion molecules, including ICAM-1, VCAM-1, and E-selectin in serum, which confirms the findings of previous studies [29–31]. Given that the inflammatory pathways in diabetes include cytokines, chemokines, and adhesion molecules, we assumed that punicalagin with its antioxidant properties might lower the levels of adhesion molecules. Notably, treatment with punicalagin promoted a significant decrease in serum levels of ICAM-1, VCAM-1,

and E-selectin in diabetic rats. One possible cause for the inhibitory effects of punicalagin on adhesion molecules might be its ability to attenuate redox-active agents in addition to its anti-inflammatory responses [32–35]. The current findings are in agreement with those presented in previous studies, which showed that phenolic substances can diminish oxidative stress and cytokines, cell adhesion molecules, and chemokines involved in cellular inflammatory responses [36]. The lowering effects of punicalagin on adhesion molecules might contribute to its anti-inflammatory effects, suggesting its potential for reducing inflammatory response in patients with diabetes.

High amounts of PC and MDA were found in the pancreas of diabetic rats, along with lower levels of antioxidants, such as GSH and decreased GPx, GR, PON-1, SOD, and CAT activities, indicating increased oxidative stress in the pancreas. This finding is consistent with prior studies, which reported increased oxidative stress in the muscles, hearts, and pancreas of animals with STZ-induced DM [12, 37, 38]. Punicalagin supplementation significantly normalized the activities of antioxidant enzymes and GSH concentrations while decreasing bioindicators of oxidative stress in the pancreas of diabetic rats, indicating the antioxidant effects of punicalagin. In addition, punicalagin significantly elevated the enzymatic and nonenzymatic antioxidants in the pancreas compared with control levels, confirming its potential ability for ameliorating oxidative stress in the pancreas given its antioxidant function [12, 39, 40]. Punicalagin was also found to prevent hyperglycemia-induced lipid peroxidation and lipid peroxides in the brain of diabetic mice [14]. Thus, the current findings clearly suggested that punicalagin is a promising natural compound for alleviating pancreatic oxidative damage associated with diabetes and that its antioxidant properties play a critical role in preventing damage of insulin-producing cells.

Along with decreased antioxidants in the pancreas, diabetic rats showed considerably higher MPO activity in the

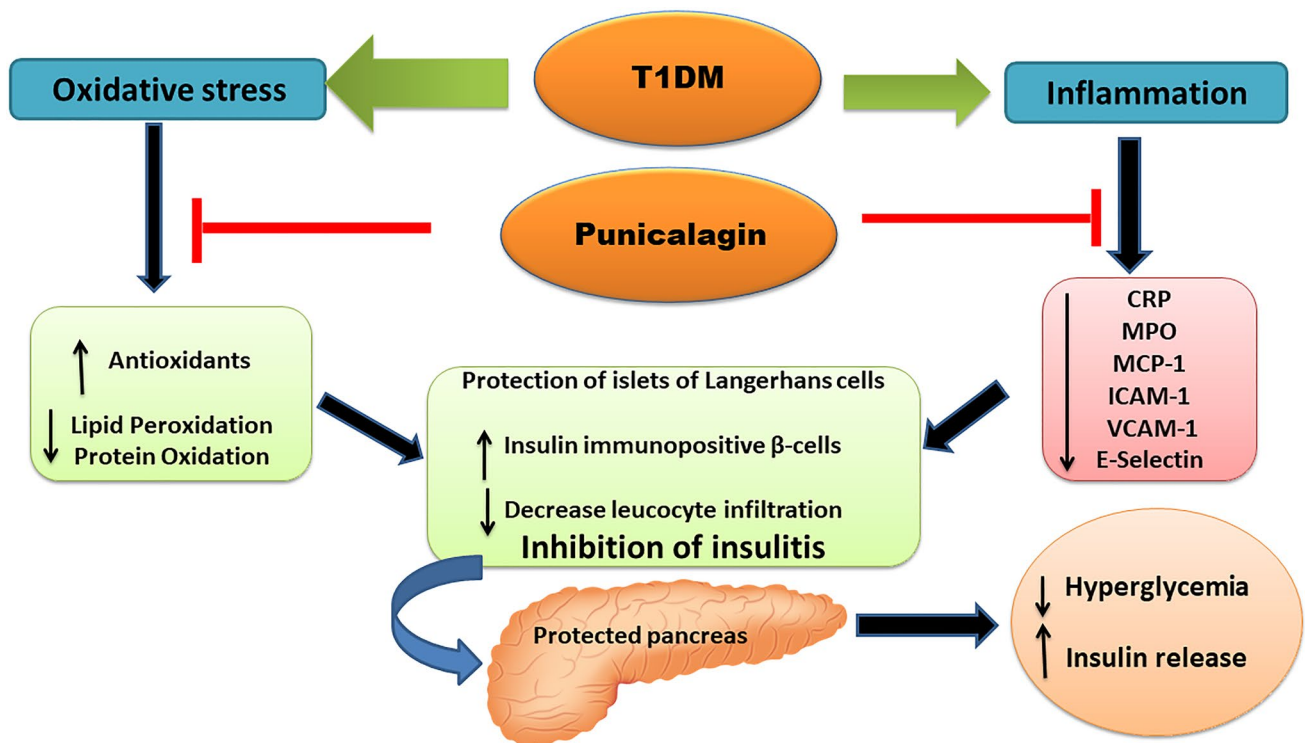


Fig. 9 Schematic diagram for the possible effects of punicalagin on protection of pancreas against STZ-induced diabetic injury

pancreatic tissue compared with control and punicalagin-treated rats. This finding agrees with the significant role played by MPO in inflammatory pathology of diseased vital organs and tissues [41], including the pancreas. Our results are in agreement with previous studies [42, 43], which found a negative association between MPO activity and antioxidant activities. This is based on the ability of MPO to release hypochlorous acid that penetrates the cell membrane and oxidizes intracellular thiols, resulting in increased oxidative stress and cellular dysfunction [44]. Given that MPO is a key factor connecting inflammation and oxidative stress in several diseases [45], we assumed that the development of MPO activity inhibitors can be a potential therapeutic approach. Punicalagin effectively reduced and subsequently normalized the elevated MPO activity in the pancreas of diabetic rats, suggesting its ability to protect pancreatic cells through its efficient antioxidative and anti-inflammatory activity. Furthermore, studies have suggested that punicalagin causes a decrease in neutrophil attraction to inflammation sites as evidenced by the decrease in MPO activity. This finding is based on the low leucocyte infiltration into the pancreas observed after treatment with punicalagin. This finding might validate the anti-inflammatory properties of punicalagin.

PON-1 exerts antioxidant effects with anti-inflammatory action [46]. Compared to control and punicalagin-treated animals, diabetic rats exhibited significant lower PON-1

activity accompanied with higher lipid and protein oxidation in the pancreas. These findings are consistent with those presented in other studies, which showed an opposite association between level of lipid peroxidation products and PON-1 activity in experiments involving rats with STZ-induced diabetes [47, 48]. This is attributed to the hyperglycemia-induced high-density lipoprotein (HDL) glycation that disrupts PON-1 binding to HDL, resulting in the inhibition of enzyme activity [49]. The present results showed that PON-1 activity was not inhibited in diabetic rats treated with punicalagin, suggesting that punicalagin can be an essential modulator of PON-1 function by preventing STZ-induced oxidative stress and/or exerting effects on the performance of enzymes that can hydrolyze lipid peroxides in pancreatic tissue [50–53]. Thus, the current findings indicate that punicalagin appears to be a promising treatment approach for preventing oxidative stress by augmenting PON-1 activity in pancreatic tissue.

The islets of Langerhans are the endocrine portion of the pancreas that plays an important role in maintaining blood glucose homeostasis [54]. T1DM negatively affects the integrity and structure of the islets caused by hyperglycemia-induced oxidative stress and inflammatory response [55]. The current study demonstrated histopathological alterations in the islets of STZ-induced diabetic rats by the decrease in their size and significant leucocyte infiltration, indicating islet dysfunction and development of insulinitis. Furthermore,

immunohistochemical staining showed a significant decrease in the number of insulin-producing β -cells in diabetic rats. These findings are consistent with the results presented in a recent study [56]. These changes were reflected by the decrease in insulin levels and hyperglycemia in sera of the same animals, implying that protecting islet structure and improving their function is a potential strategy for the treatment of T1DM. Treatment of diabetic rats with punicalagin exerted remarkable improvement in histopathological changes and increased number of β -cells with a significant decrease in leucocyte infiltration, indicating improved insulinitis and protection of pancreatic islets. Given that pyroptosis [13] and necroptosis [54] are associated with increased inflammatory response and destruction of the pancreatic β -cells, the present findings suggested that punicalagin might mitigate pancreatic cell death. This has been the first study to show that punicalagin protects the pancreas and has anti-insulinitis effects. These outcomes of punicalagin supplementation are associated with marked insulin production and normalization of blood glucose levels to almost control levels. Therefore, we suggest that punicalagin exerted its protective role against islets dysfunction and insulinitis through its anti-inflammatory and antioxidant action. The current findings support those of a study in which pomegranate peel ethyl acetate extract was used to preserve β -cells in diabetic pancreases [57]. The antioxidant action of pomegranate extract protected the existing β -cells from oxidative injury of free radicals [58].

The dose and route of administration are important factors to maximize the utility of the punicalagin. In addition, the role of punicalagin in the regulation of signal pathways and hormonal transduction to exert the ameliorative effect on pancreas and specifically β -cells should be explored.

In conclusion, treatment with punicalagin in diabetic rats protected pancreatic structure and function and improved insulinitis by controlling the increase in inflammatory cytokines and augmenting antioxidant levels in the pancreatic islets of diabetic rats (Fig. 9). Currently, we are focusing on the effects of punicalagin on apoptosis and pyroptosis to characterize the pathways and their regulating proteins in islets cells. Therefore, the beneficial effects of punicalagin can be considered a valuable finding and warrants further studies. The efficiency of punicalagin treatment should be investigated in clinical trials as an adjuvant therapy for human patients with T1DM. The current study suggests that more efforts should be devoted toward increasing the utility of punicalagin and better utilizing this natural product in clinical practice.

Supplementary Information The online version contains supplementary material available at <https://doi.org/10.1007/s11010-022-04478-1>.

Acknowledgements Facilities provided by Mansoura University are greatly acknowledged.

Author contributions All authors contributed to the study conception and design. Material preparation, data collection, and analysis were performed by HLA, BRD, LHA, AIO, MAEM, and MEA. The first draft of the manuscript was written and all authors commented on previous versions of the manuscript. All authors read and approved the final manuscript.

Funding This research received no specific grant from any funding agency in the public, commercial, or not-for-profit sectors.

Data availability All data generated or analyzed during this study are included in this published article.

Declarations

Conflict of interests None. The authors declare that they have no conflict of interest.

Ethical approval All procedures performed in this study were conducted in accordance with the regulations approved by the Ethics Committee at Faculty of Science, Mansoura University, Egypt.

Consent to participate Not applicable.

Consent to publish Not applicable.

References

- Roder PV, Wu B, Liu Y, Han W (2016) Pancreatic regulation of glucose homeostasis. *Exp Mol Med* 48:e219. <https://doi.org/10.1038/emmm.2016.6>
- Newsholme P, Cruzat VF, Keane KN, Carlessi R, de Bittencourt PI (2016) Molecular mechanisms of ROS production and oxidative stress in diabetes. *Biochem J* 473:4527–4550. <https://doi.org/10.1042/BCJ20160503C>
- Pugliese A (2016) Insulinitis in the pathogenesis of type 1 diabetes. *Pediatr Diabetes* 17:31–36. <https://doi.org/10.1111/pedi.12388>
- Fraga CG, Croft KD, Kennedy DO, Tomás-Barberán FA (2019) The effects of polyphenols and other bioactives on human health. *Food Funct* 10:514–528. <https://doi.org/10.1039/c8fo01997e>
- Stiller A, Garrison K, Gurdyumov K, Kenner J, Yasmin F, Yates P et al (2021) From fighting critters to saving lives: polyphenols in plant defense and human health. *Int J Mol Sci* 22:8995. <https://doi.org/10.3390/ijms22168995>
- Faddladdeen KAJ (2021) Ameliorating effect of pomegranate peel extract supplement against type 1 diabetes-induced hepatic changes in the rat: biochemical, morphological and ultrastructural microscopic studies. *Folia Morphol (Warsz)* 80:149–157. <https://doi.org/10.5603/FM.a2020.0034>
- Subkorn P, Norkaew C, Deesrisak K, Tanyong D (2021) Punicalagin, a pomegranate compound, induces apoptosis and autophagy in acute leukemia. *PeerJ* 9:e12303. <https://doi.org/10.7717/peerj.12303>
- Venusova E, Kolesarova A, Horky P, Slama P (2021) Physiological and Immune Functions of Punicalagin. *Nutrients* 13:2150. <https://doi.org/10.3390/nu13072150>
- Taheri Rouhi SZ, Sarker MMR, Rahmat A, Alkahtani SA, Othman F (2017) The effect of pomegranate fresh juice versus pomegranate seed powder on metabolic indices, lipid profile, inflammatory biomarkers, and the histopathology of pancreatic islets of Langerhans in streptozotocin-nicotinamide induced type 2 diabetic Sprague-Dawley rats. *BMC Complement Altern Med* 17:156. <https://doi.org/10.1186/s12906-017-1667-6>

10. Venusova E, Kolesarova A, Horky P, Slama P (2021) Physiological and immune functions of punicalagin. *Nutrients* 13:2150. <https://doi.org/10.3390/nu13072150>
11. Yu LM, Dong X, Xue XD, Zhang J, Li Z, Wu HJ et al (2019) Protection of the myocardium against ischemia/reperfusion injury by punicalagin through an SIRT1-NRF-2-HO-1-dependent mechanism. *Chem Biol Interact* 306:152–162. <https://doi.org/10.1016/j.cbi.2019.05.003>
12. El-Missiry MA, Amer MA, Hemieda FA, Othman AI, Sakr DA, Abdulhadi HL (2015) Cardioameliorative effect of punicalagin against streptozotocin-induced apoptosis, redox imbalance, metabolic changes and inflammation. *Egypt J Basic Appl Sci* 2:247–260. <https://doi.org/10.1016/j.ejbas.2015.09.004>
13. An X, Zhang Y, Cao Y, Chen J, Qin H, Yang L (2020) Punicalagin protects diabetic nephropathy by inhibiting pyroptosis based on TXNIP/NLRP3 pathway. *Nutrients* 12:1516. <https://doi.org/10.3390/nu12051516>
14. Zhong J, Reece EA, Yang P (2015) Punicalagin exerts protective effect against high glucose-induced cellular stress and neural tube defects. *Biochem Biophys Res Commun* 467:179–184. <https://doi.org/10.1016/j.bbrc.2015.10.024>
15. Jin D, Zhang B, Li Q, Tu J, Zhou B (2020) Effect of punicalagin on multiple targets in streptozotocin/high-fat diet-induced diabetic mice. *Food Funct* 11:10617–10634. <https://doi.org/10.1039/d0fo01275k>
16. El-Missiry MA, Elkomy MA, Othman AI, AbouEl-Ezz AM (2018) Punicalagin ameliorates the elevation of plasma homocysteine, amyloid-beta, TNF-alpha and apoptosis by advocating antioxidants and modulating apoptotic mediator proteins in brain. *Biomed Pharmacother* 102:472–480. <https://doi.org/10.1016/j.biopha.2018.03.096>
17. Furman BL (2015) Streptozotocin-induced diabetic models in mice and rats. *Curr Protoc Pharmacol*. <https://doi.org/10.1002/0471141755.ph0547s70>
18. Othman AI, El-Sawi MR, El-Missiry MA, Abukhalil MH (2017) Epigallocatechin-3-gallate protects against diabetic cardiomyopathy through modulating the cardiometabolic risk factors, oxidative stress, inflammation, cell death and fibrosis in streptozotocin-nicotinamide-induced diabetic rats. *Biomed Pharmacother* 94:362–373. <https://doi.org/10.1016/j.biopha.2017.07.129>
19. Janardhan KS, Jensen H, Clayton NP, Herbert RA (2018) Immunohistochemistry in investigative and toxicologic pathology. *Toxicol Pathol* 46:488–510. <https://doi.org/10.1177/0192623318776907>
20. Anggorowati N, Kurniasari CR, Damayanti K, Cahyanti T, Widodo I, Ghozali A et al (2017) Histochemical and immunohistochemical study of α -SMA, collagen, and PCNA in epithelial ovarian neoplasm. *Asian Pac J Cancer Prev: APJCP* 18:667. <https://doi.org/10.22034/APJCP.2017.18.3.667>
21. Zheng P, Li Z, Zhou Z (2018) Gut microbiome in type 1 diabetes: a comprehensive review. *Diabetes Metab Res Rev* 34:e3043. <https://doi.org/10.1002/dmrr.3043>
22. Lindsay RS, Corbin K, Mahne A, Levitt BE, Gebert MJ, Wigton EJ et al (2015) Antigen recognition in the islets changes with progression of autoimmune islet infiltration. *J Immunol* 194:522–530. <https://doi.org/10.4049/jimmunol.1400626>
23. Rhee KJ, Lee CG, Kim SW, Gim DH, Kim HC, Jung BD (2015) Extract of Ginkgo Biloba Ameliorates streptozotocin-induced type 1 diabetes mellitus and high-fat diet-induced type 2 diabetes mellitus in mice. *Int J Med Sci* 12:987–994. <https://doi.org/10.7150/ijms.13339>
24. Jialal I, Kaur H, Devaraj S (2013) Human C-reactive protein accentuates macrophage activity in biobreeding diabetic rats. *J Diabetes Complications* 27:23–28. <https://doi.org/10.1016/j.jdiacomp.2012.03.020>
25. Cvetkovic I, Al-Abed Y, Miljkovic D, Maksimovic-Ivanic D, Roth J, Bacher M et al (2005) Critical role of macrophage migration inhibitory factor activity in experimental autoimmune diabetes. *Endocrinol* 146:2942–2951. <https://doi.org/10.1210/en.2004-1393>
26. Cao Y, Chen J, Ren G, Zhang Y, Tan X, Yang L (2019) Punicalagin prevents inflammation in LPS-induced RAW264.7 macrophages by inhibiting FoxO3a/autophagy signaling pathway. *Nutrients* 11:2794. <https://doi.org/10.3390/nu11112794>
27. BenSaad LA, Kim KH, Quah CC, Kim WR, Shahimi M (2017) Anti-inflammatory potential of Ellagic acid, Gallic acid and punicalagin A&B isolated from Punica granatum. *BMC Complement Altern Med* 17:47. <https://doi.org/10.1186/s12906-017-1555-0>
28. Nguyen-Ngo C, Willcox JC, Lappas M (2020) Anti-inflammatory effects of phenolic acids punicalagin and curcumin in human placenta and adipose tissue. *Placenta* 100:1–12. <https://doi.org/10.1016/j.placenta.2020.08.002>
29. Liu L, Liu Y, Qi B, Wu Q, Li Y, Wang Z (2014) Nicorandil attenuates endothelial VCAM-1 expression via thioredoxin production in diabetic rats induced by streptozotocin. *Mol Med Rep* 9:2227–2232. <https://doi.org/10.3892/mmr.2014.2066>
30. Gustavsson C, Agardh C-D, Zetterqvist AV, Nilsson J, Agardh E, Gomez MF (2010) Vascular cellular adhesion molecule-1 (VCAM-1) expression in mice retinal vessels is affected by both hyperglycemia and hyperlipidemia. *PLoS ONE* 5:e12699. <https://doi.org/10.1371/journal.pone.0012699>
31. Asni E, Romus I (2019) The effect of alpha-lipoic acid on expression of VCAM-1 in type 2 diabetic rat. *Anat Cell Biol* 52:176–182. <https://doi.org/10.5115/acb.2019.52.2.176>
32. Asgary S, Sahebkar A, Afshani MR, Keshvari M, Haghjooyjavanmard S, Rafieian-Kopaei M (2014) Clinical evaluation of blood pressure lowering, endothelial function improving, hypolipidemic and anti-inflammatory effects of pomegranate juice in hypertensive subjects. *Phytother Res* 28:193–199. <https://doi.org/10.1002/ptr.4977>
33. Sohrab G, Nasrollahzadeh J, Zand H, Amiri Z, Tohidi M, Kimiagar M (2014) Effects of pomegranate juice consumption on inflammatory markers in patients with type 2 diabetes: a randomized, placebo-controlled trial. *J Res Med Sci* 19:215–220
34. Sohrab G, Nasrollahzadeh J, Tohidi M, Zand H, Nikpayam O (2018) Pomegranate juice increases sirtuin1 protein in peripheral blood mononuclear cell from patients with type 2 diabetes: a randomized placebo controlled clinical trial. *Metab Syndr Relat Disord* 16:446–451. <https://doi.org/10.1089/met.2017.0146>
35. Habtemariam S (2019) Medicinal foods as potential therapies for type-2 Diabetes and associated diseases: the chemical and pharmacological basis of their action, 1st edn. Academic Press
36. Bradley PP, Priebe DA, Christensen RD, Rothstein G (1982) Measurement of cutaneous inflammation: estimation of neutrophil content with an enzyme marker. *J Invest Dermatol* 78:206–209. <https://doi.org/10.1111/1523-1747.ep12506462>
37. Vanessa Fiorentino T, Prioletta A, Zuo P, Folli F (2013) Hyperglycemia-induced oxidative stress and its role in diabetes mellitus related cardiovascular diseases. *Curr Pharm Des* 19:5695–5703. <https://doi.org/10.2174/1381612811319320005>
38. Mabhidha SE, Johnson R, Ndlovu M, Sangweni NF, Louw J, Opoku A et al (2018) A Lanosteryl triterpene from *Protorhus longifolia* augments insulin signaling in type 1 diabetic rats. *BMC Complement Altern Med* 18:265. <https://doi.org/10.1186/s12906-018-2337-z>
39. Kulkarni R, Acharya J, Ghaskadbi S, Goel P (2014) Oxidative stress as a covariate of recovery in diabetes therapy. *Front Endocrinol (Lausanne)* 5:89. <https://doi.org/10.3389/fendo.2014.00089>
40. Tang D, Liu L, Ajiakber D, Ye J, Xu J, Xin X et al (2018) Anti-diabetic effect of Punica granatum flower polyphenols extract in type 2 diabetic rats: activation of Akt/GSK-3beta and inhibition of

- IRE1alpha-XBP1 pathways. *Front Endocrinol (Lausanne)* 9:586. <https://doi.org/10.3389/fendo.2018.00586>
41. Davies MJ, Hawkins CL (2020) The role of myeloperoxidase in biomolecule modification, chronic inflammation, and disease. *Antioxid Redox Signal* 32:957–981. <https://doi.org/10.1089/ars.2020.8030>
 42. Nishat S, Klinke A, Baldus S, Khan LA, Basir SF (2014) Increased A3AR-dependent vasoconstriction in diabetic mice is promoted by myeloperoxidase. *J Cardiovasc Pharmacol* 64:465–472. <https://doi.org/10.1097/FJC.000000000000139>
 43. Ojha S, Alkaabi J, Amir N, Sheikh A, Agil A, Fahim MA et al (2014) Withania coagulans fruit extract reduces oxidative stress and inflammation in kidneys of streptozotocin-induced diabetic rats. *Oxid Med Cell Longev* 2014:201436. <https://doi.org/10.1155/2014/201436>
 44. Stocker P, Cassien M, Vidal N, Thétiot-Laurent S, Pietri S (2017) A fluorescent homogeneous assay for myeloperoxidase measurement in biological samples. A positive correlation between myeloperoxidase-generated HOCl level and oxidative status in STZ-diabetic rats. *Talanta* 170:119–127. <https://doi.org/10.1016/j.talanta.2017.03.102>
 45. Ndrepepa G (2019) Myeloperoxidase—a bridge linking inflammation and oxidative stress with cardiovascular disease. *Clin Chim Acta* 493:36–51. <https://doi.org/10.1016/j.cca.2019.02.022>
 46. Kuchta A, Strzelecki A, Cwiklinska A, Toton M, Gruchala M, Zdrojewski Z et al (2015) PON-1 activity and plasma 8-isoprostane concentration in patients with angiographically proven coronary artery disease. *Oxid Med Cell Longev* 2015:5136937. <https://doi.org/10.1155/2016/5136937>
 47. Tas S, Sarandol E, Ziyank S, Aslan K, Dirican M (2005) Effects of green tea on serum paraoxonase/arylesterase activities in streptozotocin-induced diabetic rats. *Nutr Res* 25:1061–1074. <https://doi.org/10.1016/j.nutres.2005.10.001>
 48. Taş S, Sarandöl E, Dirican M (2014) Vitamin B6 supplementation improves oxidative stress and enhances serum paraoxonase/arylesterase activities in streptozotocin-induced diabetic rats. *Sci World J* 2014:351598. <https://doi.org/10.1155/2014/351598>
 49. Hedrick CC, Thorpe SR, Fu MX, Harper CM, Yoo J, Kim SM et al (2000) Glycation impairs high-density lipoprotein function. *Diabetologia* 43:312–320. <https://doi.org/10.1007/s001250050049>
 50. Rosenblat M, Hayek T, Aviram M (2006) Anti-oxidative effects of pomegranate juice (PJ) consumption by diabetic patients on serum and on macrophages. *Atherosclerosis* 187:363–371. <https://doi.org/10.1016/j.atherosclerosis.2005.09.006>
 51. Betanzos-Cabrera G, Guerrero-Solano A, Cruz-Mayorga D, Calderon Z, Villanueva-Sanchez J, Irecta AP et al (2009) Effect of pomegranate juice on paraoxonase 1 (pon1) gene expression and enzymatic activity in a streptozotocin-induced diabetes and diet-induced obese mode. *Can J Diabetes* 33:266–267. [https://doi.org/10.1016/S1499-2671\(09\)33210-4](https://doi.org/10.1016/S1499-2671(09)33210-4)
 52. Betanzos-Cabrera G, Guerrero-Solano J, Martínez-Pérez M, Calderón-Ramos Z, Belefant-Miller H, Cancino-Diaz JC (2011) Pomegranate juice increases levels of paraoxonase1 (PON1) expression and enzymatic activity in streptozotocin-induced diabetic mice fed with a high-fat diet. *Food Res Int* 44:1381–1385. <https://doi.org/10.1016/j.foodres.2011.01.042>
 53. BinMowyna MN, Binobead MA, Al Badr NA, AlSedairy SA, Elredh IAR, Al-Qahtani WS (2019) Effect of Saudi and Egyptian pomegranate polyphenols in regulating the activity of PON1, PON2 and lipid profile for preventing coronary heart disease. *BioRxiv* 2019:570838. <https://doi.org/10.1101/570838>
 54. Rojas J, Bermudez V, Palmar J, Martinez MS, Olivar LC, Nava M et al (2018) Pancreatic beta cell death: novel potential mechanisms in diabetes therapy. *J Diabetes Res* 2018:9601801. <https://doi.org/10.1155/2018/9601801>
 55. Willcox A, Richardson SJ, Bone AJ, Foulis AK, Morgan NG (2009) Analysis of islet inflammation in human type 1 diabetes. *Clin Exp Immunol* 155:173–181. <https://doi.org/10.1111/j.1365-2249.2008.03860.x>
 56. Zhao B, Wu F, Han X, Zhou W, Shi Q, Wang H (2020) Protective effects of acarbose against insulinitis in multiple low-dose streptozotocin-induced diabetic mice. *Life Sci* 263:118490. <https://doi.org/10.1016/j.lfs.2020.118490>
 57. Shalaby MF, Zaki AA, Shabana S, Osman NM (2015) Effects of Punica granatum peels extract on the Intestinal α -glucosidase activity and the histopathology of the pancreas of Alloxan-induced diabetic rats. *Egypt J Med Sci* 36:255–272
 58. Wang JY, Zhu C, Qian TW, Guo H, Wang DD, Zhang F et al (2015) Extracts of black bean peel and pomegranate peel ameliorate oxidative stress-induced hyperglycemia in mice. *Exp Ther Med* 9:43–48. <https://doi.org/10.3892/etm.2014.2040>

Publisher's Note Springer Nature remains neutral with regard to jurisdictional claims in published maps and institutional affiliations.