

Thymoquinone Protect Against Hepatotoxicity and Nephrotoxicity Induced by Carbon Tetrachloride in Mice

Nahidah Ibrahim Hammadi¹, Shaimaa Hajalan², Thana I Mustafa³, Marwan Mahmood Saleh*⁴, Eman Naji Saleh⁵

¹College of Pharmacy, University Of Anbar, Al-Anbar, IRAQ

^{5,2}College of Education for Women, University Of Anbar, Al-Anbar, IRAQ

³College of Dentistry, University Of Anbar, Al-Anbar, IRAQ

⁴College of Applied Sciences, University Of Anbar, Al-Anbar, IRAQ

E-mail: homamm728@gmail.com *

edw.shmaah.s@uoanbar.edu.iq

thanaabio2017@gmail.com

bio_marwan@yahoo.com

aemanng349@gmail.com

Article History:

Submitted: 15.11.2019

Revised: 10.01.2020

Accepted: 10.02.2020

ABSTRACT

Carbon tetrachloride (Ccl4) is a toxic substance and has been the focal point of many toxic studies in vivo and in vitro. Thymoquinone (TQ), the lively ingredient of black seed oil, might also stop oxidative infection. Therefore, we took into account the practicable impact of TQ on protection in opposition to chemical agent poisoning and at the stage of lipid peroxide, and also possesses many residences inclusive of anti-inflammatory analgesic actions. In this study, 20 mice have been divided into four subgroups, every team consisting of 5 mice, according to the concentrations as follows:: The manage group(G1) with 5 mice (n=5) that used to be administered 0.1ml corn oil IP For 24h. Group 2 dealt with group/ mice given TQ(0.25ml) for 24h, Group 3 two contaminated group/ mice gived ccl4 (0.1 ml) for 24h and Group 4 defensive group/ mice gived earlier than 24h TQ (0.25ml) (IP) and after 24 h. gived ccl4 (0.1 ml) for 24h. Histopathological examination of

the liver and kidneys confirmed obvious damage in the group that administered Carbon tetrachloride. The defensive team showed a complete reflection of toxic outcomes in liver and kidney cells, This confirms that Thymoquinone used to be providing whole protection against poisonous substances.

Key words: Carbone tetrachloride, Thymoquinone, hepatocytes , Protective

Correspondence:

Marwan Mahmood Saleh

University of Anbar

Al – Anbar, Iraq

E-mail: homamm728@gmail.com

DOI: [10.5530/srp.2020.2.17](https://doi.org/10.5530/srp.2020.2.17)

©Advanced Scientific Research. All rights reserved

INTRODUCTION

Carbon tetrachloride is recognized to be a toxic material and has attracted the interest of many ancient studies [1]. The carbon tetrachloride system is ccl4, and its molecular weight 153.8/mol. It is a clear, non-flammable liquid which is nearly insoluble in water [2]. The important effects of carbon tetrachloride are in liver, kidney, and central system [3]. The liver is an substantial organ and is vigorously concerned in unique metabolic functions [4], and it's the primary target organ of Ccl4. [5]. Two Hepatic injury by using chemicals or infectious sellers is associated with the distortion of these metabolic features [6,7]. Two The precept precipitated via ccl4 caused hepatic injury is accelerated lipid peroration and diminished things to do of antioxidant enzymes and the era of free radicals [8,9]. Chronic and acute kidney injury is also a very frequent visitor ailment caused by means of ccl4 [10]. It is known to be nephritis in as nicely as hepatotoxic to human beings [11,12], and a number of latest research showed, that ccl4 also causes problems of the lungs, kidneys, brain, and testes as well as in the blood through producing free radicals [13,14] ccl4 is allotted to all main organs as a feature of float and fat content of the tissues cell., with the easiest concentrations in the fat, liver, kidney, adrenals , bone marrow, and brain. CCL4 causes a minimize in the pastime of enzymes that defend lipid peroxide in the kidneys [15]. Thymoquinone (TQ), might also prevent oxidative injury in more than a few fashions and shield against carcinogenicity brought about by chemical agents [16]. which possesses quite a few homes along with analgesic and anti-inflammatory actions It has been propose that TQ may additionally as an antioxidant to stop the lipid peroxidation in hepatocytes hepatotoxicity

models, and acetic acid-induced colitis in rats[17]. TQ has a range of advisable houses inclusive of anti-oxidative and anti-inflammatory pastime research have to furnish authentic observation on the role of oxidative fatigue and inflammation in the evolution of renal illnesses such as glomerulonephritis and drug-induced nephrotoxicity. The protective impact of Tq has been demonstrated in animal model [18].

Experiment animal

In this experiment, 20 mice were used with close weights. They were divided into 4 groups according to the concentrations as follows: The control group (G1) with five mice (n=5) that was administered 0.1ml corn oil IP For 24h. Group 2 treated group/ mice gived TQ (0.25ml) for 24h, Group 3 infected group/ mice gived ccl4 (0.1 ml) for 24h and Group 4 protective group/ mice gived before 24h TQ (0.25ml) (IP) and after 24 h. gived ccl4 (0.1 ml) for 24h.

Histopathological Preparation

The animal was anesthetized after 24 hours and the liver and renal tissue samples were cut to about 0.5 cm3 and kept in 10% formalin for 48 hours. Tissue preparing (lack of hydration, cleaning, infiltration) was done normally using mechanized tissue processor (Leica TP1020).

RESULTS

Histopatho- investigation of the liver

Histopathological examination of liver tissue of control crew treated by using corn oil, show regular figure1(A), also group treated by TQ normal, which has ordinary architecture, had been central vein, portal tract,

hepatocyte and sinusoids show up normal As figure1(B). The dealt with group by way of ccl4, liver section of mice revealed an excessive distortion of hepatic architecture. Shown zonal necrosis affecting positive sector in the liver e.g. centrilobular necrosis and congestion blood vessels due to positive toxic material ccl4 figure1 (C). Micro vesicular due to steatosis (fatty changes) in most cells the well-preserved nucleus is squeezed into the displaced rim of cytoplasm about the vacuole, the fat in cytoplasm pushed the nucleus to the peripheral of the cell membrane of hepatocyte figure1 (D). two Hepatocellular degeneration -centrilobular necrosis is proven in figure1 (E), inflammatory polymorph leucocytes are displaying in sinusoidal house are flooded with inflammatory cells and RBCs. The shielding group, of animals group, Showed a whole reversal of poisonous results on liver cells. , The central vein and triangles of the portal are normal. Some liver cells confirmed binucleation figure1 (F) Studies in laboratory mice point out that hepatic toxicity is the the prevailing non-cancer impact of subchronic or persistent exposure to ccl4. In this study, directory of hepatic harm liver histopathology (necrosis,fatty degeneration, and fibrosis) irritation and regenerative pastime [19,20, 21]. Two the outcomes of the present learn about point out that i.p.adminisreation of TQ may protect

the liver against toxicity brought about by ccl4 in mice. The outcomes of previous research point out that TQ (12.5mg/kg.ip) can also play an vital important role as an antioxidant and can also correctly act as defensive marketers against chemically-induced hepatic damage [22]. Carbon tetrachloride was idea to injury the liver phone mitochondria, it used to be suggested that lipid accumulation was due to a failure of regular pathways of lipid oxidation, This can be inferred from Cyminum Cuminum Pledged to guard from ethanol via Keep up with the preservation of the acid-base balance of Stomach content [23,34]. The find out about through the pound, investigated that hepatic necrosis of ccl4 24 or 28 h accelerated the hepatocellular tumor [24]. A single dose of ccl4 two when administrated to rat produced centrilobular necrosis and fatty degeneration of the liver [25]. TQ avoided oxidative damage in hepatocytes prompted by using ccl4.[26,27]. Naji et al confirmed that administration of TQ in signal dose earlier than of ccl4 It has a role in protecting the liver from poisoning caused by ccl4 in mice. [28]. Mansour et al was recommended that TQ may additionally act as an antioxidant agent and stop the membrane lipid peroxidation in hepatocytes as executed with the respective control agencies [29]

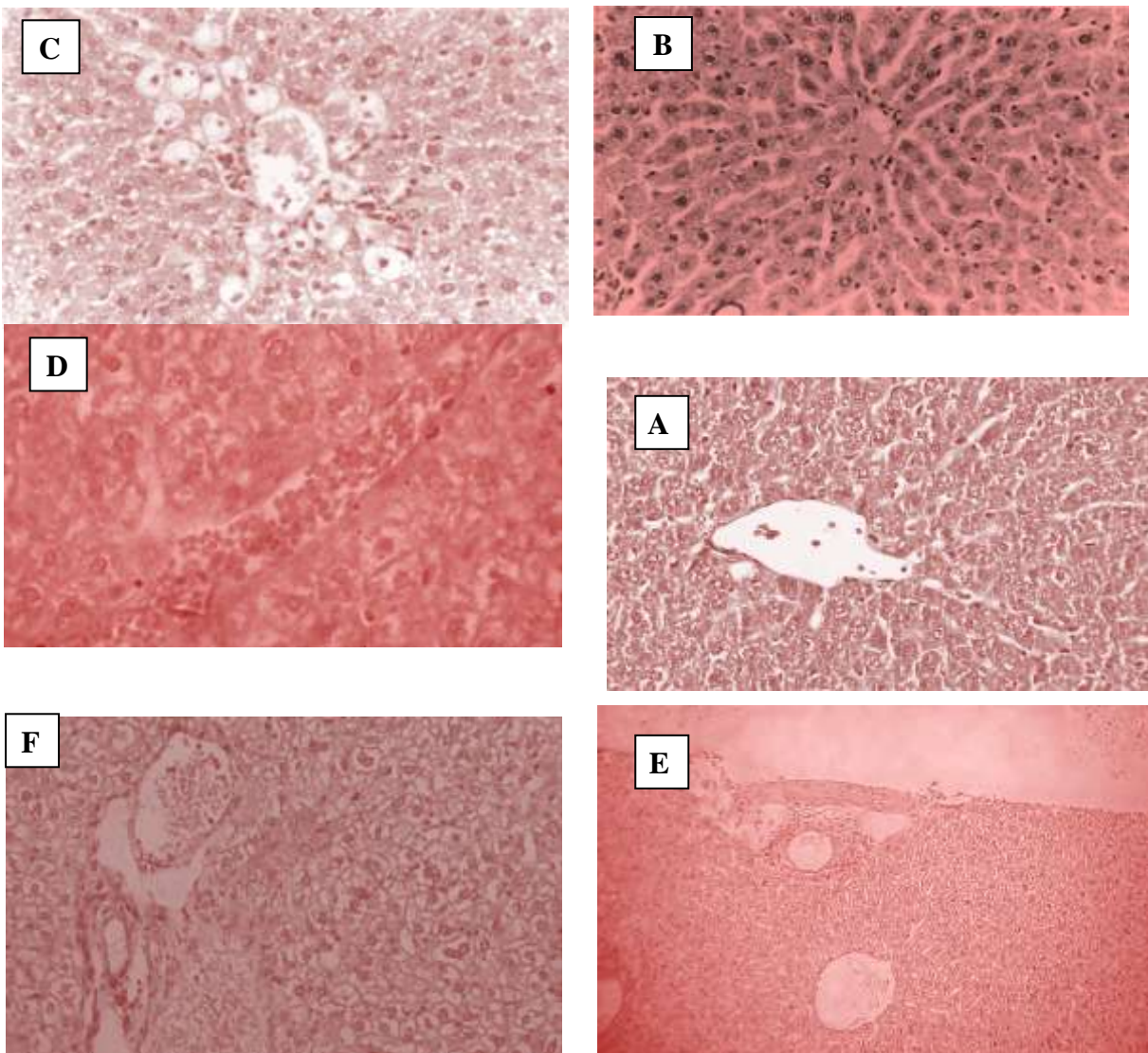


Figure 1: Section of liver ,(A)control showing normal histology,(B) Liver treated with thymoquinon (TQ) showing normal histology when compare with control group,(C,D and E) The treated group by ccl4 showing necrosis, centrilobular fatty changes, and inflammatory infiltrate and (Steatosis),and degeneration &Acute -centrilobular necrosis.(F) The protective group, The central vein and portal triads appear normal.

Histopatho-investigation of the kidney

Histopathological examination of the Section of kidney tissue of control group showing normal histology is shown in Figure 2(A). While kidney sections of normal mice treated with corn oil shown and the group treated with thymoquinone no histopathological changes. Which has normal architecture, where the normal proximal and distal convoluted tubules and normal glomeruli also seen is shown in Figure 2(B). The kidney section of the mice in the CCl₄ treated group revealed dilatation and congestion of renal blood vessels. and lost their characteristic and their lining epithelial cells became undistinguished. Inter tubular leukocytes Infiltrations were observed diffused necrosis of renal tubule and mononuclear infiltration into interstitial due to certain toxic material CCl₄ shown in Figure 2(C). The Protective group (Tq +CCl₄) treated animals of Group-V: showed complete reversal of toxic effects in the kidney tissue renal tubules were seen to be intact with well-defined and clear lumens. Kidney tending

towards control Figure 2 (D).. The histopathological result of ccl4 induced group, show dilatation and congestion of renal blood vessel, most of renal tubules were damaged and lost their characteristic appearance their lining epithelial cells became undistinguished. Glomeruli and tubules, our study was agreed with [30]. Reports by Perez et al., And Ujitorok, indicated that exposure to ccl4 causes chronic and acute renal injuries (30). Additionally, various reports have demonstrated that ccl4 produces kidney disease in humans [31]. A number of recent studies have shown that in addition to liver problems, ccl4 also causes kidney and also blood disorders by generating free radicals. [32]. Present study was conducted to evaluate the protective effect of (TQ+ ccl₄) against ccl4 induced renal disorder in mice, complet reversal of toxic effects in the kidney tissue. The antioxidant action of TQ may explain the protective effect of these agents against various nephrotoxic model in vivo (33).

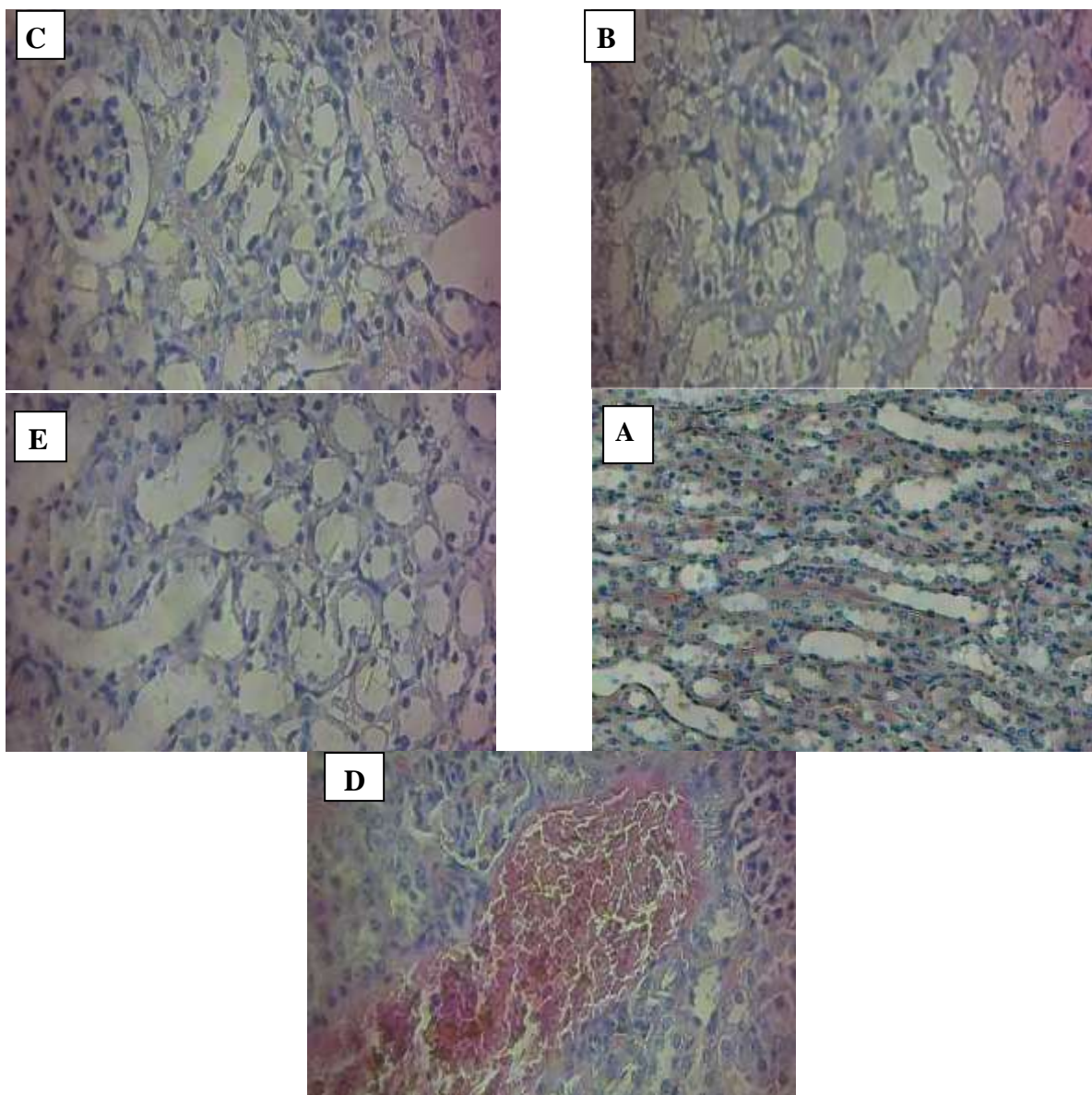


Figure: (2) Section of kidney tissue ,(A)control group treated with corn oil . Glomeruli and tubules appear normal, (B) treated thymoquinone no histopathological changes.(C ,D) CCl4 treated group shown vascular dilated and congestion around the tubules and shown extensive vacuolization Glomeruli and tubules,(E) The Protective groups (Tq + CCl4) complete reversals of toxic effects in the kidney tissue renal tubules were seen to be intact with well-defined and clear lumens. Similar histological structure to that of control mice.

REFERENCES

1. Packer, J. E., Slater, T. F., & Willson, R. L. (1978). Reactions of the carbon tetrachloride-related peroxy free radical (CCl₃O₂.) with amino acids: Pulse radiolysis evidence. *Life sciences*, 23(26), 2617-2620.
2. Atlanta, GA.(1994). Agency for Toxic substances and Disease registry. Toxicological profile for carbon tetrachloride. Public health service, U.S. Department of Health and human services
3. Hazard summary-created in april (1992). revised in jun 2000. Carbon tetrachloride.
4. Essawy, A. E., Abdel-Moneim, A. M., Khayyat, L. I., & Elzergy, A. A. (2012). Nigella sativa seeds protect against hepatotoxicity and dyslipidemia induced by carbon tetrachloride in mice. *J Appl Pharm Sci*, 2(10), 021-025.
5. Abdel-Fattah, A. F. M., Matsumoto, K., & Watanabe, H. (2000). Antinociceptive effects of Nigella sativa oil and its major component, thymoquinone, in mice. *European journal of pharmacology*, 400(1), 89-97.
6. Wolf, P. L. (1999). Biochemical diagnosis of liver disease. *Indian Journal of Clinical Biochemistry*, 14(1), 59-90.
7. Cullen, J. M. (2005). Mechanistic classification of liver injury. *Toxicologic pathology*, 33(1), 6-8.
8. Poli, G. (1993). Liver damage due to free radicals. *British medical bulletin*, 49(3), 604-620.
9. Ohta, Y., Kongo, M., Sasaki, E., Nishida, K., & Ishiguro, I. (2000). Therapeutic effect of melatonin on carbon tetrachloride-induced acute liver injury in rats. *Journal of pineal research*, 28(2), 119-126.
10. Relevance to public health.(1990). background and environmental exposures to carbon tetrachloride in the United States .
11. Manna, P., Sinha, M., & Sil, P. C. (2006). Aqueous extract of Terminalia arjuna prevents carbon tetrachloride induced hepatic and renal disorders. *BMC complementary and alternative medicine*, 6(1), 33.
12. Ogeturk, M., Kus, I., Colakoglu, N., Zararsiz, I., Ilhan, N., & Sarsilmaz, M. (2005). Caffeic acid phenethyl ester protects kidneys against carbon tetrachloride toxicity in rats. *Journal of ethnopharmacology*, 97(2), 273-280.
13. Abraham, P., & Wilfred, G. (1999). Oxidative damage to the lipids and proteins of the lungs, testis and kidney of rats during carbon tetrachloride intoxication. *Clinica chimica acta; international journal of clinical chemistry*, 289(1-2), 177-179.
14. Kind, P. R. N., & King, E. J. (1954). Estimation of plasma phosphatase by determination of hydrolysed phenol with amino-antipyrine. *Journal of clinical Pathology*, 7(4), 322.
15. Bonaventura, J., Schroeder, W. A., & Fang, S. (1972). Human erythrocyte catalase: an improved method of isolation and a reevaluation of reported properties. *Archives of Biochemistry and Biophysics*, 150(2), 606-617.
16. Dogukan, A., Akpolat, N., Celiker, H., Ilhan, N., Bahcecioglu, L.H., Gunal, A.L., (2003). Protective effect of interferon - α on carbon tetrachloride-induced nephrotoxicity in various. *Biomedical Research* 10, 141-145
17. Daniels, W. M., Reiter, R. J., Melchiorri, D., Sewerynek, E., Pablos, M. I., & Ortiz, G. G. (1995). Melatonin counteracts lipid peroxidation induced by carbon tetrachloride but does not restore glucose-6 phosphatase activity. *Journal of pineal research*, 19(1), 1-6.
18. Ragheb, A., Attia, A., Eldin, W. S., Elbarbry, F., Gazarin, S., & Shoker, A. (2009). The protective effect of thymoquinone, an anti-oxidant and anti-inflammatory agent, against renal injury: a review. *Saudi Journal of Kidney Diseases and Transplantation*, 20(5), 741.
19. Noguchi, T., Fong, K. L., Lai, E. K., Alexander, S. S., King, M. M., Olson, L., ... & McCay, P. B. (1982). Specificity of a phenobarbital-induced cytochrome P-450 for metabolism of carbon tetrachloride to the trichloromethyl radical. *Biochemical pharmacology*, 31(5), 615-624.
20. Bruckner, J. V., MacKenzie, W. F., Muralidhara, S., Luthra, R., Kyle, G. M., & Acosta, D. (1986). Oral toxicity of carbon tetrachloride: acute, subacute, and subchronic studies in rats. *Fundamental and applied toxicology*, 6(1), 16-34.
21. Hayes, J. R., Condie Jr, L. W., & Borzelleca, J. F. (1986). Acute, 14-day repeated dosing, and 90-day subchronic toxicity studies of carbon tetrachloride in CD-1 mice. *Toxicological Sciences*, 7(3), 454-463.
22. Koporec, K. P., Kim, H. J., MacKenzie, W. F., & Bruckner, J. V. (1995). Effect of oral dosing vehicles on the subchronic hepatotoxicity of carbon tetrachloride in the rat. *Journal of Toxicology and Environmental Health, Part A Current Issues*, 44(1), 13-27.
23. Al Gharably, N. M., Badary, O. A., Naji, M., Al Shabanah, O. A., Al Sawaf, H. A., & Al Rikabi, A. C. (1997). Protective effect of thymoquinone against carbon tetrachloride-induced hepatotoxicity in mice.
24. Recknagel, R. O. (1967). Carbon tetrachloride hepatotoxicity. *Pharmacological Reviews*, 19(2), 145-208.
25. Pound, A. W. (1978). Influence of carbon tetrachloride on induction of tumours of the liver and kidneys in mice by nitrosamines. *British journal of cancer*, 37(1), 67.
26. Slater, K.H., Cheeseman, K., & Ingold, F.R.S. (1985). Carbon tetrachloride toxicity as model for studying free-radical mediated liver injury. *Biological Sciences*, Vol.311, No.1152 (Dec.17, pp.633-644.

27. Daba, M. H., & Abdel-Rahman, M. S. (1998). Hepatoprotective activity of thymoquinone in isolated rat hepatocytes. *Toxicology Letters*, 95(1), 23-29.
28. Nagi, M. N., Alam, K., Badary, O. A., Al-Shabanah, O. A., Al-Sawaf, H. A., & Al-Bekairi, A. M. (1999). Thymoquinone protects against carbon tetrachloride hepatotoxicity in mice via an antioxidant mechanism. *IUBMB Life*, 47(1), 153-159.
29. Mansour, M. A., Ginawi, O. T., El-Hadiyah, T., El-Khatib, A. S., Al-Shabanah, O. A., & Al-Sawaf, H. A. (2001). Effects of volatile oil constituents of *Nigella sativa* on carbon tetrachloride-induced hepatotoxicity in mice: evidence for antioxidant effects of thymoquinone. *Research communications in molecular pathology and pharmacology*, 110(3-4), 239-252.
30. Bashandy, S. A., & AlWasel, S. H. (2011). Carbon tetrachloride-induced hepatotoxicity and nephrotoxicity in rats: Protective role of vitamin C. *J Pharmacol Toxicol*, 6(3), 283-292.
31. Habig, W. H. (1974). S-transferases: the first enzymatic step in mercapturic acid formation. *J. Biol. Chem.*, 249, 7130-7139.
32. Esterbauer, H., & Cheeseman, K. H. (1990). [42] Determination of aldehydic lipid peroxidation products: malonaldehyde and 4-hydroxynonenal. In *Methods in enzymology* (Vol. 186, pp. 407-421). Academic Press.
33. Kind, P. R. N., & King, E. J. (1954). Estimation of plasma phosphatase by determination of hydrolysed phenol with amino-antipyrine. *Journal of clinical Pathology*, 7(4), 322.
34. Alkubaisy, S. A., Saleh, M. M., Yaseen, M. M., Salih, O. A., Qader, S. W., & Saleh, E. N. (2019). Evaluation study of the anti-ulcer activities of *Cuminum cyminum* Seed extract against ethanol-induced gastric ulcer in rats.