

Research Article

Toxicopathological study for comparison the toxic effect of celecoxib and ibuprofen on liver and kidney of male albino mice

MUHAMMED M. AL-ANI¹, ABDULRAHMAN A. ZAHER², ALI A. TALA'A³, MAISAM KHIDER AL-ANII⁴¹Department of Pharmacology and toxicology, Collage of Pharmacy-University of Anbar.²Department of Pharmacy, University Isra'a College.³Department of Histology and Embryology, Collage of Veterinary Medicine-University of Fallujah.⁴Department of Basic science, Collage of Dentist-University of Anbar.

Received: 09.07.20, Revised: 24.08.20, Accepted: 19.09.20

ABSTRACT

The object of this study were to evaluate the toxic effect of celecoxib and ibuprofen with regard toxicopathological changes in mature male albino mice. Non-steroidal anti-inflammatory drugs (NSAIDs) must be prescribed with carefulness as courses of just a few days, even at amounts within prescribing recommendations, can be related with serious adverse effects in some patients. The cyclo-oxygenase-1 and 2 (COX-1 and COX-2) enzymes produce prostaglandins (PGs) after the metabolism of omega-6 polyunsaturated fatty acid (arachidonic acid). PGs are chemical messengers that mediate inflammation, fever and the sensation of pain. The analgesic and anti-inflammatory effects of NSAIDs are produced by the prevention of PGs production by prevention of COX activity. Clinical effects and the risk profiles of the different NSAIDs are main factors to select which one are the best to achieve its function and by their variance ability to inhibit the COX-1 and/or COX-2 enzymes and their half-lives.

Keywords: Toxic effect, celecoxib, ibuprofen.**INTRODUCTION**

NSAID used in the treatment of osteoarthritis, rheumatoid arthritis, acute pain, painful menstruation and menstrual symptoms, and is also used to reduce numbers of colon and rectum polyps in patients with familial adenomatous polyposis [Clemmettd,Goakl 2000]. NSAIDs cause an increased risk of serious gastrointestinal or intestines adverse events including bleeding, ulceration and perforation which can be lethal, these can occur at any period of usage and without cautioning signs. Ageing patients are at bigger danger for serious gastrointestinal, liver and kidney events. Ibuprofen is a non-selective inhibitor of enzyme COX, which is responsible for convert arachidonic acid to prostaglandin [Croffoord LJ.,2000]. Ibuprofen is extensively metabolized in liver to inactive pharmacologically metabolites and excreted via kidney following biotransformation to glucuronide conjugate. The excretion of conjugates may be tied to renal function and the accumulation of conjugates occurs in end-stage renal and hepatic disease (Fakhreddin Jamali and Dion R. Brocks 2015). Celecoxib is highly selective reversible inhibitor of the COX-2 isoform of cyclooxygenase, celecoxib inhibits the transformation of arachidonic acid to prostaglandin precursors [Grosser et al., ,2006]. After oral administration, celecoxib is quickly

absorbed and reach peak serum concentration in around 3 hrs. It is mainly metabolized in the liver, with very little drug (< 3%) being excreted unchanged [PaulsonSK,et al.,2000]. The main route of excretion for celecoxib is in urine [Solomon et al. ,2008].

MATERIALS AND MTHODS**Experimental animals**

A total number of thirty male Albino mice weighed (75-85 g) were used in this study. Their ages ranged between 6-7 months. Animals in all periods of the experiment were housed in plastic cages in conditioned room (22-25°C) in the animal house of College of pharmacy – Al-Anbar University, with manually controlled lightening providing daily light of twelve hours (7.00 AM to 19.00 PM) and twelve hourss night cycle. They were left for seven days for adaptation with the experimental conditions. Animals had free access to water and diet along the experimental period. Mice were randomly divided into three equal groups (10rat/group) and administered orally for 30 days by using special gavage needle as the following: C group rats that received ordinary distilled water and served as control, T1 group mice of this group were administrated 1.25 mg/kg B.W of celecoxib, T2 group mice of this

group were administrated 35 mg/kg B.W of ibuprofen.

Blood Sampling

Fasting blood (for 12 hrs.) samples were collected at the end of the experiment, blood was drawn by cardiac puncture technique from anesthetized rats intramuscular injection of Ketamine (90mg/Kg B.W.) and xylazine (40mg/Kg B.W.). The blood samples were collected in tube containing EDTA for biochemical tests. Blood samples were used for measurements of Creatinin level, urea level, potassium level, GOT, GPT and chloride level.

RESULTS

Alkaline Phosphatase

Histological studies

Mice were anesthetized, sacrificed by withdrawal of blood from heart. Immediately, after scarification, the kidney and liver were excised blotted and tissue specimen and preserved in 10% neutral formalin buffer solution till the preparation of histological sections. Several tissue sections were prepared according to (Lee, G. and Luna,L.G. 1968)

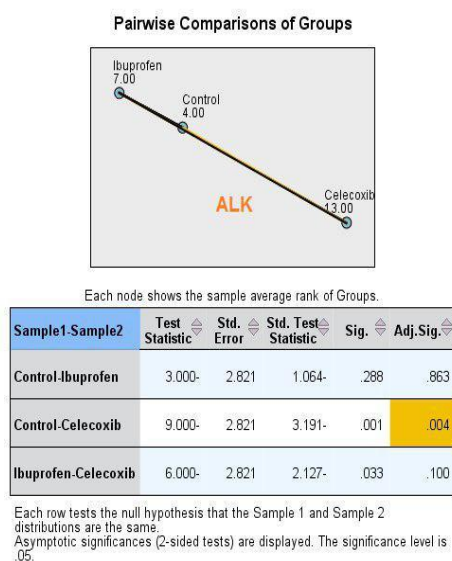


Fig.1: show the differences of Alkaline phosphatase between control group, celecoxib treated group and ibuprofen group during experimental period

Urea level

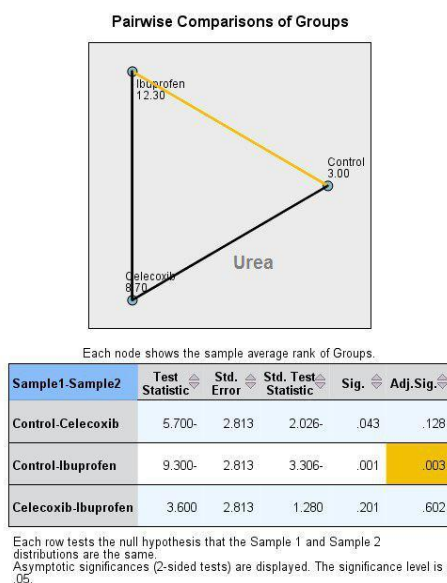


Fig.2: show the differences of Urea level between control group, celecoxib treated group and ibuprofen group during experimental period.

Chloride Level

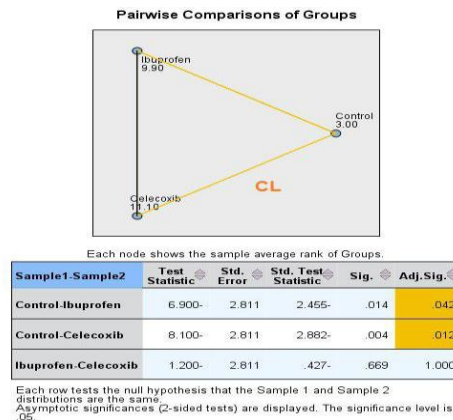


Fig.3: show the differences of Clearance level between control group, celecoxib treated group and ibuprofen group during experimental period.

Creatinine level

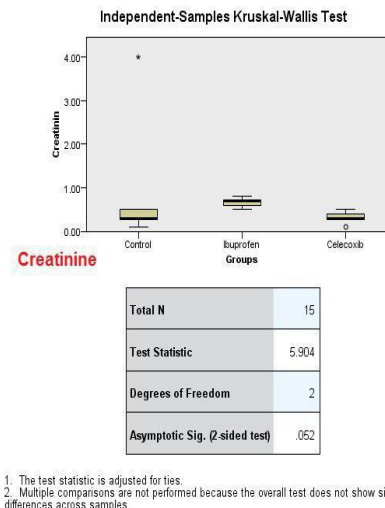


Fig.4: show the differences of Creatinine level between control group, celecoxib treated group and ibuprofen group during experimental period.

GOT

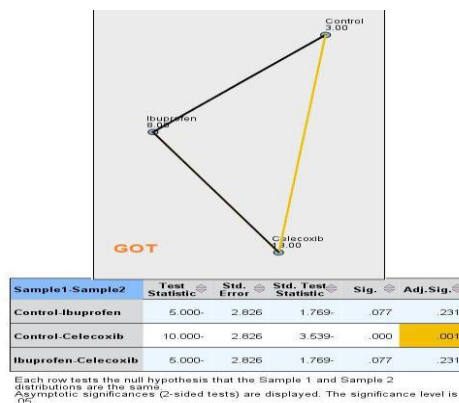


Fig.5: show the differences of GOT between control group, celecoxib treated group and ibuprofen group during experimental period.

GPT

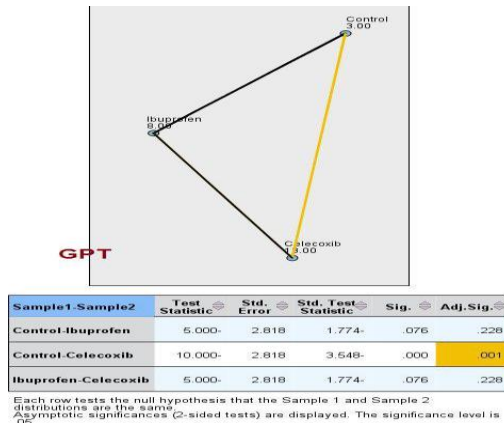


Fig.4-6: show the differences of GPT between control group, celecoxib treated group and ibuprofen group during experimental period.

Potassium level

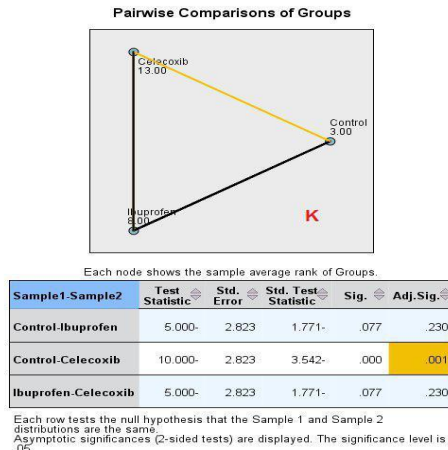


Fig.7: show the differences of Potassium level between control group, celecoxib treated group and ibuprofen group during experimental period.

Sodium level

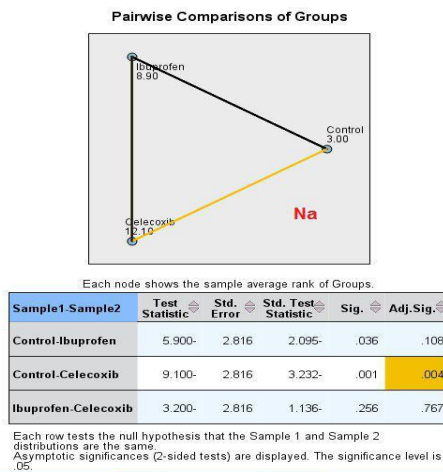


Fig.8: show the differences of Sodium level between control group, celecoxib treated group and ibuprofen group during experimental period.

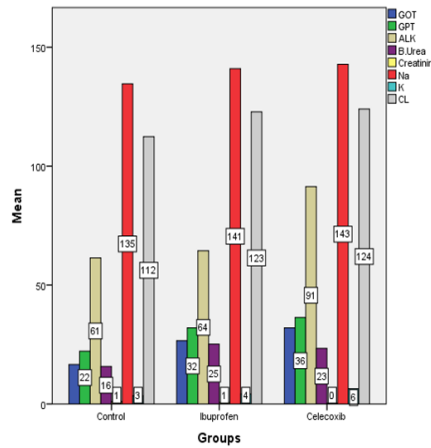


Fig.9: show the abstract in change of all studied parameters comparing all group control group, celecoxib treated group and ibuprofen group during experimental period.

Histopathological study

Control group and T1 group: There were no significant microscopic findings in the control untreated group and also celecoxib group used in the experiment (figure 10 A,B).

Treated group T2: After 30 day of treatment the liver showed sinusoidal atrophy with hepatocyte swelling with sever inflammatory cell cuffing swelling. Kidney: Showed tubular epithelia with hydroponic degeneration with microgranuloma formation (figure 11 and 12).

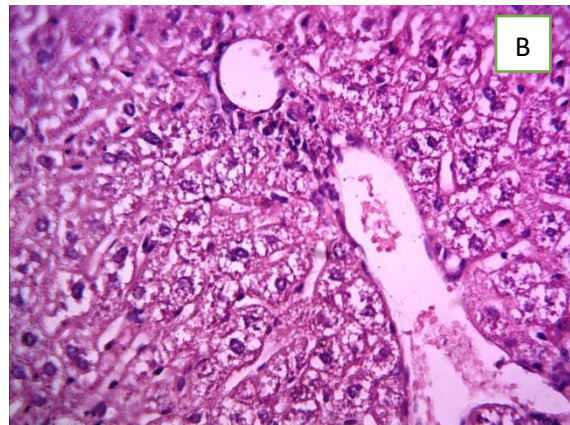
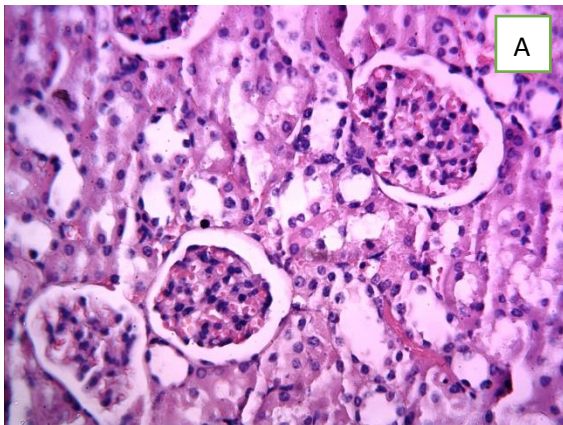


Fig.10: A: Histophotographic image for kidney and B: for liver mice treated with Celecoxib showed no histopathological abnormal changes H&E X40.

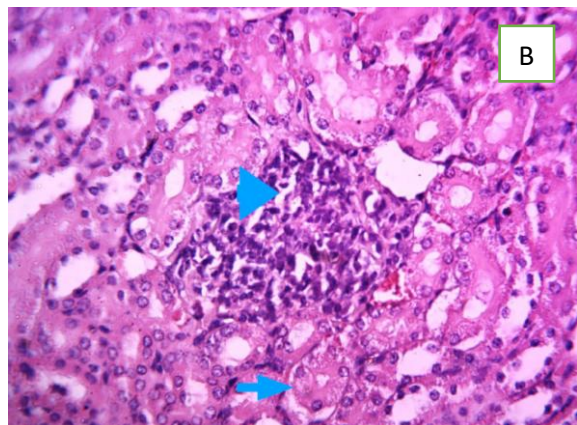
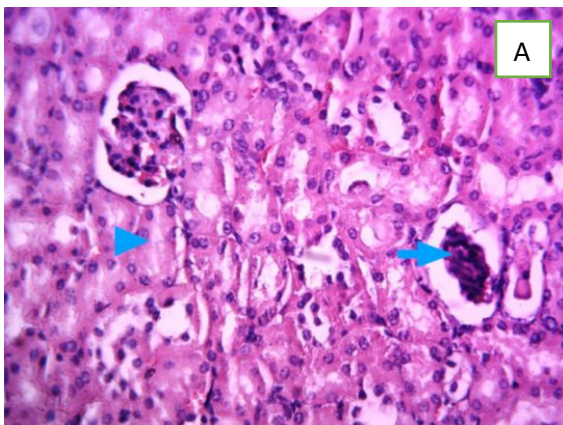


Fig.11: Histophotographic image of rat kidney from treated group with liboprofen. A: showed glomerular atrophy (arrow) with sever acute cellular swelling (arrowhead), B: showed tubular

epithelia with hydropic degeneration (arrow) with microgranuloma formation (arrowhead)H&E X40.

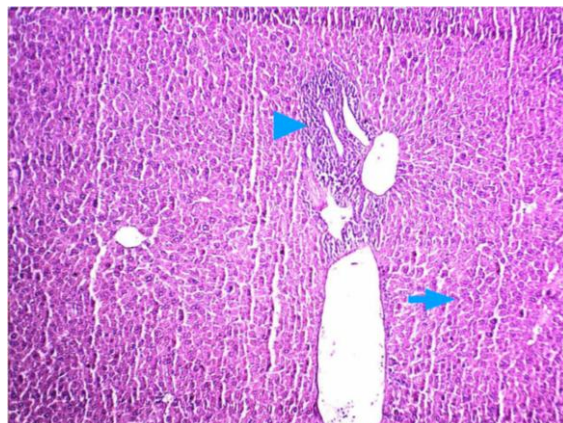


Fig.12: Histopathographic image of rat liver from treated group with liboprofen showed sinusoidal atrophy with hepatocyte swelling (arrow) with sever inflammatory cell cuffing swelling (arrowhead) H&E X40.

DISCUSSION

Rendering to the present study, we observed the chronic administration of Ibuprofen group resulted in the induction of histopathological abnormalities of hepatic and renal tissues of the mice comparing with histopathological results for group that administered celecoxib that appear a histopathological results more closed for placebo group.

The activities of GOT, GPT and ALP are commonly used as biochemical pointers of liver functions. Structural and functional changes in the liver result in raised levels of these enzymes in blood. The levels of these aminotransferases (GOT and GPT) in serum are raised in all liver diseases, in acute hepatitis a very high levels of more than 1000 parts can be seen (Vasudevan DM., 2007). we clearly demonstrate that both ibuprofen and celecoxib administration lead to biochemical alterations which showed significant findings for liver and kidney, while for histopathological change there are no significant change in celecoxib group when compared with control and ibuprofen group.

CONCLUSION

From our results it can be concluded that damage reported in kidneys and livers of ibuprofen treated group was proportional with the biochemical results and vice versa with celecoxib treated group.

REFERENCES

1. Lee, G. and Luna, L.G. (1968). Manual of histological staining methods of Armed Forces institutes of pathology. 3rd ed. Mc Grow-Hill Book Company. New York. Pp: 12-31.

2. Clemett D, Goa KL. (2000). Celecoxib: a review of its use in osteoarthritis, rheumatoid arthritis and acute pain. *Drugs*. ;957-980.
3. Crofford LJ. (2002). Specific cyclooxygenase-2 inhibitors: what have we learned since they came into widespread clinical use current opinion rheumatology. 14:225-230.
4. Fakhreddin Jamali and Dion R. Brocks (2015). The Pharmacokinetics of Ibuprofen in Humans and Animals, *Ibuprofen*, (81-131).
5. Grosser T, Fries S, FitzGerald GA. (2006). Biological basis for the cardiovascular consequences of COX-2 inhibition: therapeutic challenges and opportunities. *J Clin Invest*. ;116:4-15.
6. Paulson SK, Hribar JD, Liu NW, Hajdu E, Bible RH, Jr, Piergies A, Karim A. (2000). Metabolism and excretion of [(14)C]celecoxib in healthy male volunteers. *Drug Metab Dispos*. 28:308-314.
7. Simmons DL, Botting RM, Hla T. (2004). Cyclooxygenase isozymes: the biology of prostaglandin synthesis and inhibition. *Pharmacol Rev*. ;56:387-437.
8. Vasudevan DM, Sreekumari S. Textbook of Biochemistry for Medical Students. 5th ed. New Delhi: Jaypee Brothers Medical Publishers Ltd.;2007.