



## Human Vermiform Appendix Of Different Age Groups

Mohammed.J. salih <sup>1</sup>; Abdul jabbar .J. Mehdi <sup>2</sup>; Samira .A-H. Abdullah <sup>2</sup>

1- University of Anbar, College of Pharmacy. Clinical and Laboratory Science department.

2- University of Tikrit, College of medicine. Anatomy department.

E.Mail : [Mhmd.jasim69@gmail.com](mailto:Mhmd.jasim69@gmail.com)

### ARTICLE INFO

Article History

Received:1/1/2020

Accepted:26/1/2020

### Keywords:

Weight, Length,

Diameter;

Vermiform

appendix

### ABSTRACT

**Background:** Many works have been carried out related to the worm-like vermiform appendix in humans. It is characterized by a large number of lymphoid tissues. The important feature of this structure at a young age is the presence of large and numerous lymphoid follicles in both layers of mucosa and submucosa.

**Objective:** The aim of the present investigation was to find out the age and sex-related changes among adult Iraqi vermiform appendix anatomically.

**Materials & methods:** Fifty normal human cadavers were selected. Of the total number of cadavers, 30 males and 20 females were included. All the cadavers were divided into age groups. For each cadaver, weight, length, and width were measured.

**Results:** appendix weight in males was higher than females for all age groups. The length of the appendix was also more in males than in females. External diameter varied from the base towards the tip. The diameter of the base was higher in the middle and the tip regions. These values were more in males than in females.

**Conclusion:** The weight, length, and diameter of the vermiform appendix in males were more than in females. The diameter of the appendix is more at the base than at the middle and the tip regions.

### INTRODUCTION

The worm-like human vermiform appendix was included in many studies (Patel & Naik, 2016; Ahmad, *et al.*, 2017; Mohammadi, *et al.*,2017). This structure add lymphocytes to the human immune system (Rahman, *et al.*, 2008) through the numerous large lymphatic follicles especially in the young ages of human life (Chaudhari, *et al.*,2013; Bornali & Sekhar *et al.*, 2016). The vermiform appendix varies in lengths and diameters for the different populations (El-amin *et al.*,2015). Sex differences were also seen (Rahman *et al.*,2008; Bornali & Sekhar 2016).

### MATERIALS AND METHOD

Fifty normal human adult cadavers were selected after obtaining permission from a police station, and the institution of forensic medicine. The total number of cadavers included 30 males and 20 females. The age range was from 20-70 years.

The study was continued over the period from December 2017 to January 2019. The inclusion criteria for the cadavers selection were; Bullet injuries, brain stroke, angina pectorals, car accident, and sudden death. The exclusion criteria were cadavers with a grossly inflammatory, gangrenous, perforated appendix. The cadavers were divided according to age groups; group A(20-29); B(30-39); C(40-49); D(50-59); And E(60-70) years. Weights, length, and external diameters were recorded.

## RESULTS AND DISCUSSION

### Length of Appendix:

Table (1) shows the mean length of the vermiform appendix of in different study groups of the present study. The length of the vermiform appendix ranged from 10.58 cm in group (A) to 5.02cm in group (E) of male and from 9.46cm group(A) to 4.38cm in group (E) of female. The highest mean length of vermiform appendix was in group A and the lowest was in group E in both genders. There is a gradual decrease in length with increasing age groups. And the male length of vermiform appendix was slightly longer than the female. (Figure -1).

### Weight of Appendix:

Appendix weight reported in this study was also higher in males than in females, and there is a gradual decrease with age groups. Wherefrom the highest weights of appendix was 7.64g in group(A) and lowest was 4.13g in group(E) of male while highest weights were 7.21g in group (A) and lowest was 3.51g in group (E) of female. (table-1&Figure-2)

### Appendix External Diameter:

Table(3), shows the external diameter measurements for males and females. In the present study, the average external diameter of the appendix at the base in males was 5.10 mm and in females, 4.68 mm and in the middle was 4.67mm in male and in female 4.48 mm also at the tip in male

4.22mm and 4.03mm in the female. The maximum mean external diameter at base was 6.68 mm in group A male, the minimum mean external diameter of the appendix in the tip was 2.11mm in group E female. (Table-3 and Figs-3&4).

The shorter length in the age group 36-70 years in both sexes could be related to atrophy and due to the migration of lymphocytes to the lymphatic system and nodes. The mean length of appendix was 8.52 cm (range 0.5-16 cm) (Mohammadi *et al.*, 2017). While the mean length in the present work was 7.89 cm (range 5.02-10.58 cm) in males, and the mean length in females was 7.02 cm (range 4.38-9.46 cm). Their result was higher than the present result. While the present result was found to be longer than a study performed in Germany, Where the mean length was 6.3 cm (Mohammadi *et al.*, 2017), but it is shorter than mentioned in Gray's anatomy, which has mentioned an average length of 9cm (range 2-20 cm). Other study conduction in Africa showed the variation in measurement of appendix in Kenian society to be 7.65cm and 11.7cm in Zambian population, So (Chaisiwamongkol *et al.*, 2010) reported that the average length in male and female cadavers are 6.329cm and 5.688cm respectively.

The average appendicular weight was found to be 6.33g in males and in females was 6.46g in an Iranian study (Mohammadi *et al.*, 2017). While the weight of the present work found the male and female weight of appendix to be 5.84g and 5.43g respectively. So with advancing age, there is gradually especially after the third decade of life decrease the weight of vermiform appendix. Usually, the weight is related to the length. The shorter length is with a small weight, and the longer appendix is with more weight.

The present study shows the male external diameter is more than

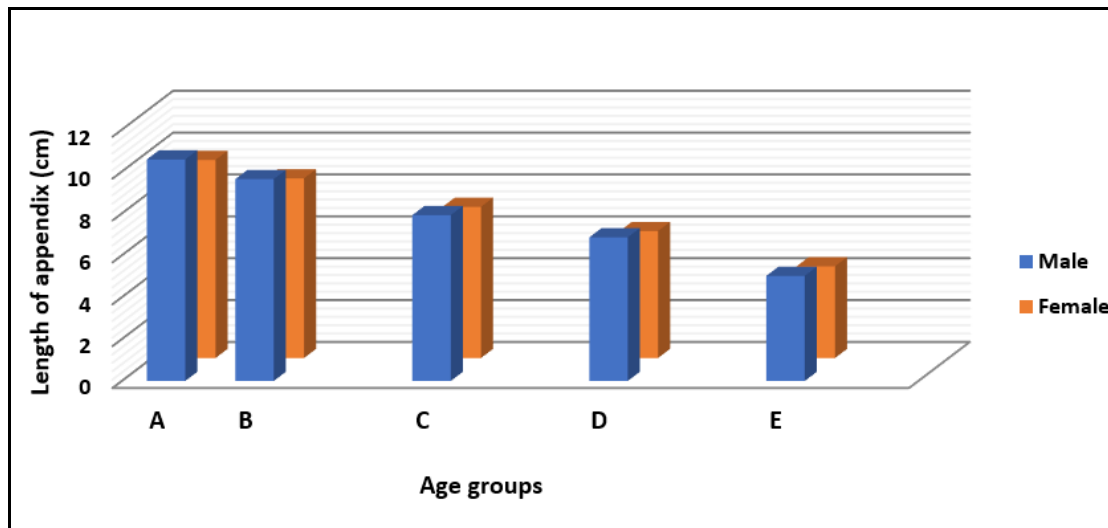
females for all regions of the appendix; The base, middle and tip. This finding was similar that seen in other studies conducted by ( Setty & Katikireddi 2013) (Jagdish & Ashoka 2018) they reported that, the average of appendix diameter at base was 6mm in male and in female 5.42mm respectively. The external diameters of appendix for the male and female at the various appendicular parts were decreasing with increasing age groups. (Ajmani

1983) stated that, there is a significant correlation between the diameter of the appendix and increasing age, the appendix becoming narrower with age. The appendicular diameter was more at the base, followed by the middle and then the tip, these findings were in agreement with (Sumi *et al.*, 2018) who founded the appendix diameter measurements revealed gradual decrease from the base toward middle and tip regions.

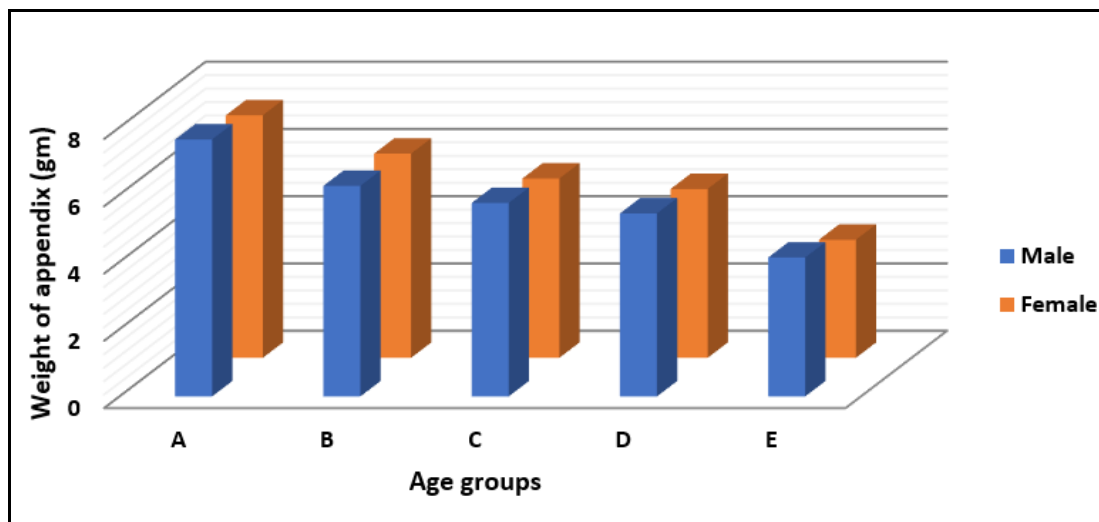
**Table 1:** Shows the means  $\pm$  SD of the length and weight of vermiform appendix

Sex Groups	Length of appendix(cm)		Weight of appendix(gm)	
	Male	Female	Male	Female
A	10.58 $\pm$ 1.26 A	9.46 $\pm$ 1.19 A	7.64 $\pm$ 0.89 A	7.21 $\pm$ 1.26 A
B	9.64 $\pm$ 1.38 AB	8.58 $\pm$ 1.23 AB	6.26 $\pm$ 1.21 AB	6.07 $\pm$ 1.02 AB
C	7.92 $\pm$ 1.12 B	7.22 $\pm$ 1.01 B	5.75 $\pm$ 1.18 B	5.33 $\pm$ 1.15 B
D	5.77 $\pm$ 1.24 CD	5.06 $\pm$ 0.97 CD	5.44 $\pm$ 0.76 BC	5.02 $\pm$ 0.92 BC
E	5.02 $\pm$ 0.99 D	4.38 $\pm$ 0.79 D	4.13 $\pm$ 1.03 C	3.51 $\pm$ 0.85 C

The different capital letters refer to significant differences between different ages at ( $P \leq 0.05$ ).



**Fig.1:** Length of vermiform appendix of human male and female in all groups.



**Fig.2:** Weight of vermiform appendix of human male and female in all groups

**Table 2:** Means and standard deviation of male and female length of appendix for different age groups(Jagdish & Ashoka 2018).

Age groups (years)	Male (cm)	Female (cm)
0-20	7.891 ±1.647	8.519 ±2.556
21-35	9.327 ±2.764	10.36 ±1.904
36-50	8.774 ±2.773	7.693 ±1.395
51-70	7.580 ±1.816	6.592 ±3.226

**Table 3:** External Diameter of vermiform appendix of human male and female in all groups

Sex groups	Base External Diameter		Middle External Diameter		Tip External Diameter	
	Male	Female	Male	Female	Male	Female
A	6.68± 1.01 A	6.39± 0.89 A	6.22± 0.94 A	5.64± 1.05 A	5.39± 1.02 A	5.19± 1.13 A
B	6.56 ± 0.94 A	5.79± 1.12 A	5.96± 1.01 A	5.27± 0.98 A	5.37± 0.88 A	5.17± 0.91 A
C	5.52± 1.03 AB	4.87± 1.07 AB	4.95± 0.58 AB	4.56± 0.84 AB	4.46± 0.81 AB	4.22± 0.69 AB
D	4.29± 0.87 B	4.14± 0.99 B	3.91±0.87 B	3.74± 0.73 B	3.58± 0.58 B	3.48± 0.48 B
E	2.39± 1.07 B	2.21± 0.80 C	2.31± 0.61 C	3.19± 0.92 B	2.28± 0.65 B	2.11± 0.71 B

The different capital letters refer to significant differences between different ages at ( $P \leq 0.05$ ).

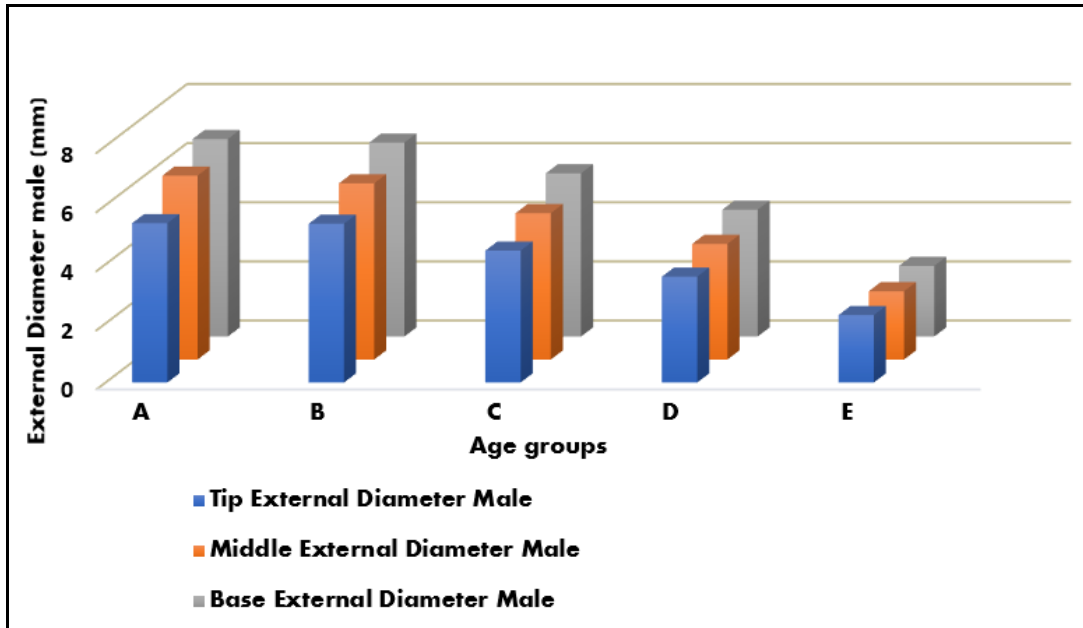


Fig.3: External diameter of vermiform appendix at(Base, middle and tip) in human male in all groups

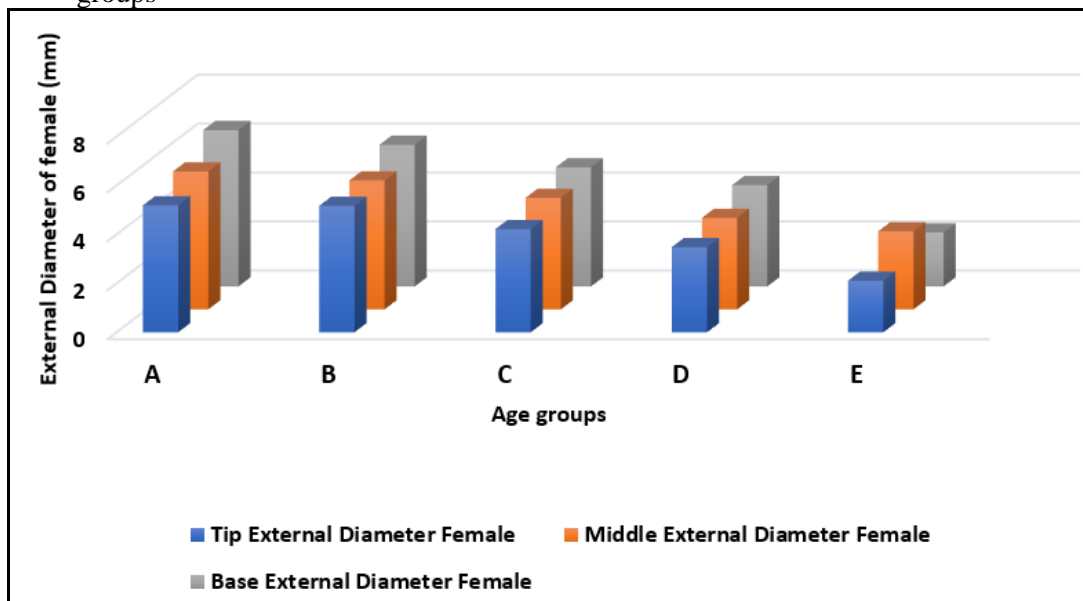


Fig.4: External diameter of vermiform appendix at(Base, middle and tip) in human female in all groups

**Conclusion**

In this study, the following conclusions can be made. The lengths of appendix, weights, and external diameters are more in males than in females. Also, the external diameter is decreasing with increasing age groups.

**REFERENCES**

Ahmad, M. A.; Ali, M. T.; Zarkoon, N. & Khan, N. M. (2017). Variations in the Position and

Length of the Vermiform Appendix in Pakistani Population. *pakistan journal of medical & health sciences*. 11(1), 356-361.

Ajmani ML, Ajmani K.(1983) The position, length and arterial supply of vermiform appendix. *Anatomischer Anzeiger*. 153: 369-74.

- Bornali, H& Sekhar D R.(2016). A Study on Length of Human Appendix in Different Ages. *IJHRMLP*. 2 (2): 101-106.
- Chaisiwamongkol, K; Chantaupalee, T; Techataweewan, N; (2010). Position Variation of Vermiform Appendix in Northeast Thai Cadavers. *Srinagarind Med J*. 25: 250–255.
- Chaudhari, M L; Kapadia D M; Kanani S D; Patel J P; Shah R K & Nirvan Ashok B. (2013). A study of morphology of vermiform appendix in 200 Cases, *Int J Med Res Health Sci*. 2(4): 780-785.
- El-amin EI.; Ahmed GY; Ahmed WAM; Khalid E.K & Sakran, AM. (2015). length and position of vermiform in Appendix among Sudanese Cadavers. *AIMS Medical Science*. 2(3): 222-227.
- Jagdish, P & Ashoka, RK. (2018). Morphometry of Vermiform Appendix: A Human Cadaveric study. *Journal of Dental and Medical Sciences*. 17(8): 72-76.
- Mohammadi,S; Hedjazi,A; Sajjadian, M; Rahmani, M; Mohammadi, M & Moghadam MD. (2017). Morphological variations of the vermiform appendix in Iranian cadavers: a study from developing countries. *Folia morphologica*. 76(4):695-701.
- Patel,S and Naik, A. (2016). Study of the length of vermiform appendix. *Indian Journal of Basic and Applied Medical Research*. 5: 256–260.
- Rahman, MM; Khalil, M; Khalil, M;Jahan, MK; Shafiquazzaman, M& Parvin B. (2008). Mass of the Vermiform Appendix in Bangladeshi People. *Journal of Bangladesh Society of Physiologist*. 3:8-12.
- Setty SN, Katikireddi RS. (2013) Morphometric study of human cadaveric caecum and vermiform appendix. *International Journal of HealthSciences and Research*. 3(10):48-55.
- Sumi SA, Sultana SZ, Mannan S, Naushaba H, Begum J, Kishwara S, Rahman MR, Chowdhury MS, Ahmed MS, Uddin MM, Ara ZG. (2018) External Diameter of Vermiform Appendix in Bangladeshi People of Different Age & Sex. *Mymensingh medical journal*. 27(3):487-95.