

Histopathology of the liver affected With Aflatoxins in broiler chicks

S. A. Lafi*, N. A.Taha** and S. M.H. Al-Genabi*

*College of Medicine\ University of Anbar

** College of Dentistry\ University of Anbar

Abstract

The study was conducted to show the effects of aflatoxine on histopathological picture of the liver of broiler chicks. Twenty five rose broiler chicks had been claimed 42 days of age reared in broiler form in Heat/ Al- Anbar province. The criteria of diagnosis of aflatoxicosis depends upon, clinical signs, mortality rate and postmortem exam, of the cases. The liver of all birds were inspected grossly, after cervical dislocation and necropsied.

Liver fragments were collected in 10% neutral buffered formalin. Tissue section 5 Mm thick were stained with hematoxylin and eosin and used for histopathological evaluation. Gross inspection of the liver showed enlargement congestion with pale patches. The histopathological changes in liver tissues include hyper plasia, congestion, necrosis, cirrhosis accumulation of RBC and inflammatory cells around the central vein.

دراسة نسيجية مرضية لكبد فروج اللحم المصابة بسموم الافلاتوكسين

شهاب أحمد لافي*، نجم الدين عبد الله طه** وسميعة مجبل حمد الجنابي*

* كلية الطب/ جامعة الأنبار

** كلية طب الأسنان/ جامعة الأنبار

الخلاصة

الغرض من الدراسة معرفة تأثير سموم الافلاتوكسين على الصورة النسيجية المرضية لكبد فروج اللحم أجريت الدراسة على 25 فروجه من اللحم من سلالة الروز في حقل في الأنبار وبعمر 42 يوم شخصت الحالات بإصابتها بالافلاتوكسين لمتداداً على العلامات السريرية والتشريح المرضي ونسبة الهلاكات. تم فحص الكبد بعد إجراء التشريح المرضي بعد قتل الطير. جمعت عينات من الكبد ووضعت في محلول متعادل من الفورمالين 10% قطعت النماذج نسيجياً ووضعت بالهيماتوكسلين ايبوسين. لغرض قراءة التغيرات النسيجية المرضية. لوحظ في الفحص العياني للكبد وتضخم في الكبد ومع وجود احتقان مع شحوب في لونه. أظهرت التغيرات النسيجية، جود فرط تنسج في خلايا الكبد، احتقان، تنكز مع حدوث تلف في النسيج الكبدي. لوحظ تجمع الخلايا الحمراء والتهاب حول الأوردة المركزية.

Introduction

Aflatoxins are produced by fungi of genus *Asperigillus*, particularly *A.flavous*, *A.parasiticus* and *A.nomius* (1). Seventeen metabolites have been identified as aflatoxins, with aflatoxin B1 (AFB1) being the most commonly found metabolite in cereals and the one that exhibits the highest toxigenic effects (2). Aflatoxins causes a great biochemical changes includes, energy carbohydrates and lipids, nucleic acid and protein metabolism (3). Their biological effects include carcinogenicity, mutagenicity, teratogenicity and hepatotoxicity (4). Aflatoxins are afrequent problem for poultry production resulting in poor bird performance (2), which is caused by several factors including reduced activity of pancreatic enzymes, decreased concentration of bile (4), increased incidence of leg problems, injury to the sciatic nerve (Lessons and summers, 1988), and antagonism in the metabolism of vitamins, proteins and amino acids, lipids, carbohydrates and damage (4,5,6).

Aflatoxin causes a variety of effects in poultry, including a decrease in body weight gain and efficiency of feed utilization. In poultry AFB1 is associated with liver damage, poor performance and immunosuppression. Liver characteristically show biliary and nodular hyperplasia and are pale and enlarged as aresult of aflatoxicosis (7,8). The study was aimed to show the effect of aflatoxicosis on histopathological picture of the liver in broiler chicks.

Material and Methods

Twenty five rose broiler chicks had been claimed at 42 days of age reared in abroiler farm in Heat/ Al- Anbar province. The criteria of diagnosis of aflatoxicosis depends upon, clinical signs, mortality rate and postmortem exam of the cases. The liver of all birds were inspected grossly. After cervical dislocation and necropsied liver fragments were collected in 10 percent neutral buffered formalin. Tissue section 5Mm thick were stained with hematoxylin and eosin and used for histopathological evaluation (9).

Results

The clinical signs appeared on the chicks include; reduction in feed consumption, depression, ruffled feathers, Closed eye, Stunted growth, purple discoloration of feet and leg and lameness ataxia, convulsions, opisthotonus preceded death. At necropsy, liver and kidneys were enlarged and pale. Some cases had hydropericardium and ascites, shrunken firm nodular liver, bil distended gall bladder and may be hemorrhagic. The histopathology of livers of broiler chicks stained with hematoxylin and eosin showed multifocal and varied cytoplasmic vaculation with perilobular location. Some hepatocytes have small pyknotic nuclei, very mild infiltration of polymophonuclear leukocytes is also present (Fig. 1). There are hepatocellular degeneration and swelling due to hydropic degeneration and fatty changes.

The bile ducts showed hyperplasia and hetrophilic infiltration (Fig.2). Bile duct proliferation and mononuclear infiltration in the portal triad with mild hydropic degeneration of hepatocytes. There is also hemorrhage and centrilobular to massive hepatocellular necrosis (Fig. 3). There is a proliferation of fibroblast with fibrous tissue formation around blood vessels which extend to hepatic tissue (Fig. 4).

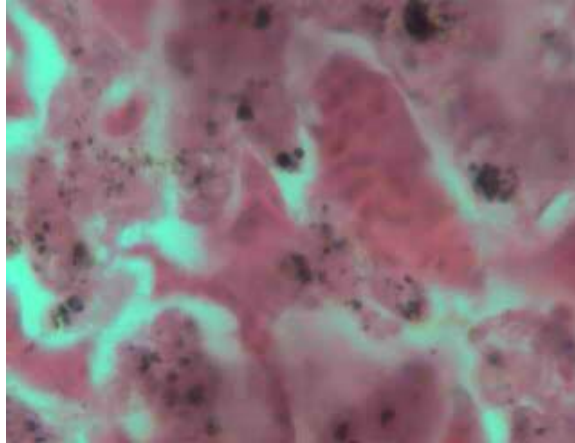


Fig (1) Numerous fat containing vacuoles of widely varying size in liver

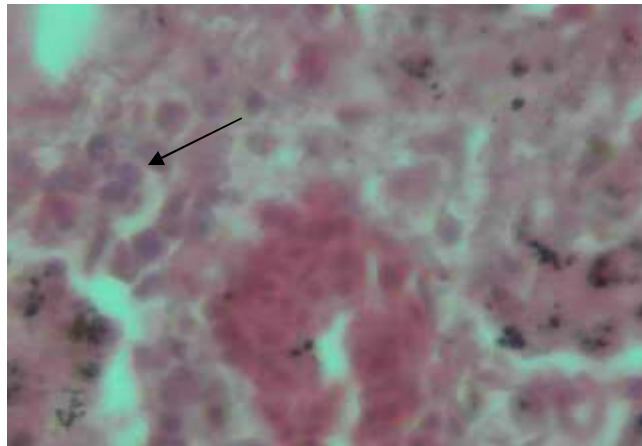


Fig (2) Swelling due to hydropic degeneration in liver

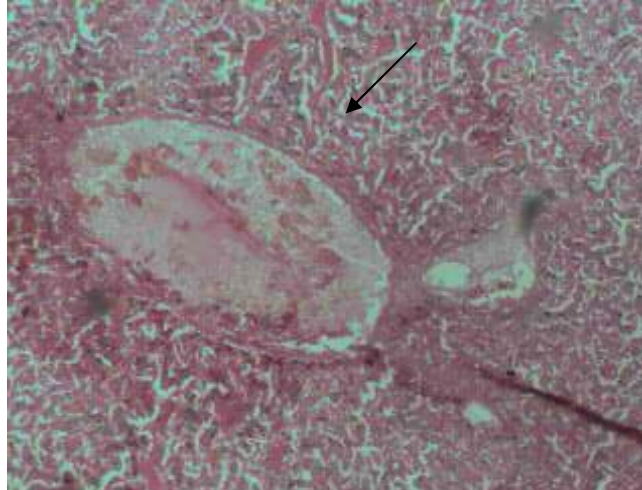


Fig (3) Bile duct proliferation and mononuclear infiltration of PMNs. Hemorrhage and centrilobular to massive hepatocellular necrosis

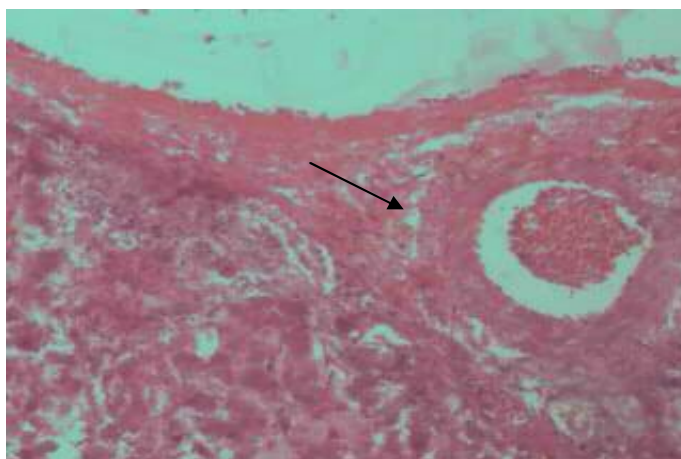


Fig (4) Fibrosis. Fibrous tissue around the blood vessel and extend to the hepatic tissue

Discussion

Aflatoxicosis is an important to the poultry industry because of their toxicity and frequency of occurrence in feed stuffs. It produces great economic losses affecting ducklings, broilers, layers, turkeys and quail. Aflatoxin impairs all important productive parameters including weight gain , feed in take, feed conversion efficiency (10,11,12). The symptoms noticed on affected birds, which includes; anemia, paralysis and lameness, ruffled feathers, closed eye, stunted growth Ataxia and convulsions is similarly observed by other workers (10,11,13,14).

The study revealed the harmful effect of Aflatoxins exposure to broiler liver tissue. These effects include hyperplasia, necrosis, cihrosis and fibrosis of the liver in infected chicks. This is in agreement with the observation of many research workers (15, 16, 17).This might be due to damage caused by aflatoxin to liver tissue and bile duct (18). The most characteristic gross lesions appeared in the livers which were enlarged, pale yellow to grayish brown and had a prominent reticular pattern. petecheal hemorrhages were observed on the surface of some livers, gall bladders were enlarged and bile duct distended (12,19) The liver, spleen and kidney were increased in size, where as the bursa of fabricius decreased (10,12). The histopathological picture observed in our study had been previously noticed by other research workers (13, 19,20). It was concluded from this study that Aflatoxins caused a great liver damage and may require to anew approach to treat the aflatoxin contaminated feed stuff.

References

1. Moss, M.O. (1998). Recent studies of mycotoxins. J. Appl. Microbial. Symp.,84:62s – 76s.
2. Lesson, S.; Diaz, G. J. & Summers, J. D. (1995). Poultry metabolic Disorders and mycotoxins, Univer. Books, Guelph, Canada.
3. Ellis, W.O.; Smith, J. P. & Simoson, B. K. (1991). Aflatoxin in food; occurrence, biosynthesis, effects on organisms, detdction and methods of control. Crit. Rev. food Sci. Nutr., 30:403-439.

4. Coulomb, R. A. (1991). Aflatoxins In;mycotoxins and phytoalexins; Sharma, R.P., Salunkhe, D.K.,Ed.;CRCpress; Boca Raton, FL,USA.
5. Tung, H.T.; Cook, F.W.; Wyatt, R. D. & Hamillon P.B. (1995).The anemia caused by aflatoxin. *Poult.Sci.*,54:1962-1969.
6. Huff, W.E.; Kubena, L.F.; Heavey, R.B.; Carrier, D.E. & Mollenhauer, H.H. (1986). Progression of aflatoxicosis on broiler chickens. *Poult. Sci.*, 65:1891-1899.
7. Kubena, L.F.; Harvey, R.B.; Philips, T.D.; Corrier, D.E. & Huff, W.E. (1990). Diminution of aflatoxicosis in growing chickens by the dietary addition of a hydrated , Sodium calcium aluminosilicate. *Poult. Sci.*,69:727-735.
8. Phillips, T.D.; Abo-norag, M.; Edrington, T.S.; Kubena, L.F. & Harvey, R.B. (1995). Influence of a hydrated sodium calcium a luminosilicate and Virginiamycin on aflatoxicosis in broiler chicks. *Poult. Sci.*, 74: 626-632.
9. Thomson, R.E. (1990). *Pathologia Veterinaria ESP ecialmanole: Sao Paulo, Brazil.*
10. Calnek, B.C.; Barnes, H.J.; McDougald, L.R. & Saif, Y.M. (1997). *Diseases of poultry, 10th Ed., Mosby Wolfe, ISU press, Ames , Iowa, U.S.A., PP. 951- 979.*
11. Saif, Y.M. (2003). *Diseases of poultry, 11th Ed., Black well publishingco ISU press. U.S.A., PP.1109-1113.*
12. AgAg, B.I. (2004). Mycotoxins in foods and feeds 1- Aflatoxin: Review Articles., *Ass.univ. Bull. Environ. Res.*, 7 (1):173-206.
13. Jones, F.T.; Hagler, W. H. & Hamilton, P.B. (1982). Association of low levels of aflatoxin in feeds with productivily Losses in commercial broiler operations. *Poult. Sci.*, 61:86-868.
14. Okoye, J.O.A.; Asuzu, I.U. & Gugnani, J.C. (1988). Paralysis and Lamness associated with aflatoxicosis in broilers. *Avian Pathol.*,17:731-734.
15. Espada, Y.; Ruiz, G. R.; Cuadradas, C. & Cabanes, F.J. (1997). Fumonisin mycotoxicosis in broilers: plasma proteins and Coagulation modifications. *Avian Dis.*,1:73-79.
16. Miazzo, R.; Rosa, C.A.R.; De Queiroz Carvalho, E.C.; Magnoli, C.; chiacchiera, S.M.; Palacio, G.; Saenz, M. & Kikot, A. (2000). Efficacy of synthetic zeolite to reduce the toxicity of aflatoxin in broiler chicks. *Poult. Sci.*, 79:1-6.
17. Tessari, E.N.C.; Kobashigawa, E.; Cardoso, A.L.S.P.; Ledoux, D.R.; Rotting haus, G.E. & Oliveira, C.A.F. (2010). Effects of aflatoxin B1 and fumonisin B1 on blood biochemical parameters in broilers. *Toxins.*, 2:453-460.
18. Ortatatli, M. & Oguz, H. (2001). A meliorative effects of dietary clinoptilolite on pathological changes in broiler chickens during aflatoxicosis. *Res. Vet . Sci.*, 71:59-66.
19. Asuzu, I.U. & Shetty, S.N. (1986). Acute aflatoxicosis in broiler chicken in nsuka Nigeria. *Trop. Vet.*, 4:79-80.
20. Dafalla, R.; Yagi, A.I. & Adam, S.E.I. (1987). Experimental aflatoxicosis in Hybro – type chicks : Sequential changes in growth and serum constituents and histopathological changes. *Vet. Hum. Toxical.*, 29:222-225.