

## Histochemical study of effect of black seed oil extract (Nigella Stavia) on liver tissue of fat feeding male rabbits

S. M. H. Al-Genabi  
College of Medicine\ Al- Anbar University

### Abstract

This study aimed to investigate the histochemical effect of black seed oil extract on liver tissue in fat feeding rabbits. The study included fifty rabbit males were divided equally into 5 groups:

1. Control group which treated with normal saline as control (C), and fed normal diet.
2. The second group (ch) was fed normal diet with 1% cholesterol for 90 days.
3. The third group (chn) was treated with oil extract of Black seed as 500 mg/ kg of body weight for each animal by oral tube, in addition to 1% cholesterol for 90 days.
4. The fourth group (Nch) was treated with oil extracts of Black seeds as 500 mg/kg by gastric tube for 30 days, and then fed cholesterol only for 60 days.
5. The fifth group (N) was treated with oil extracts of Black seeds as 500 mg/kg by gastric tube mixed with normal diet for 90 days.

The animals dissected in regular times to get the liver samples for histological and histochemical study by use special stains. Histopathological study was revealed fibrosis in liver tissue and the proliferation of bile ducts in (ch) group while the group Nch and N did not show any tissue changes significantly. The chn group was show simple changes which returned to normal at the end of experiment. These results were detected to role of black seed oil extract in reduced the harmful effect of cholesterol. This study shows the role of black seed oil in reduced influence of cholesterol on the tissues.

### دراسة كيميائية نسيجية لتأثير المستخلص الزيتي للحبة السوداء على نسيج الكبد لذكور الأرانب المغذاة على عليقة دهنية

سميحة مجبل حمد الجنابي  
كلية الطب/ جامعة الأنبار

### الخلاصة

هدفت الدراسة التعرف على تأثير المستخلص الزيتي للحبة السوداء على التصلب العصيدي المحدث تجريبياً في الأرانب والتي تضمنت دراسة نسيجية كيميائية للتغيرات المرضية في الكبد. أجريت التجربة على خمسين أرنباً من الذكور البيضاء البالغة ولمدة 90 يوماً وزعت إلى خمس مجاميع متساوية كل مجموعة احتوت على عشرة أرانب وهي مجموعة السيطرة التي جرعت بالمحلول الفسلي وأعطيت غذاء طبيعياً، بينما أعطيت المجموعة الثانية ch غذاء طبيعياً مضافاً له الكوليستيرول بتركيز 1% ولمدة 90 يوماً. أما المجموعة الثالثة chn فقد جرعت بالمستخلص الزيتي للحبة السوداء وبجرعة قدرها 500 ملغم/كلغم من وزن الجسم لكل حيوان بواسطة الأنبوب المعدي وتغذيتها على غذاء غني الكوليستيرول ونسبة 1% ولمدة 90 يوماً. أما المجموعة الرابعة Nch فقد جرعت بمستخلص زيت حبة البركة بجرعة قدرها 500 ملغم/ كلغم لكل حيوان بواسطة الأنبوب المعدي لمدة 90 يوماً غذاء طبيعياً لمدة 30 يوماً ثم أعطيت بعد ذلك غذاء غنياً بالكوليستيرول لمدة 60 يوماً بالإضافة للتجريب. أما

المجموعة الخامسة N فقد جرعت حيواناتها بمستخلص زيت الحبة السوداء بجرعة قدرها 500 ملغم/ كلغم من وزن الجسم لكل حيوان باستخدام الأنبوب المعدي فضلاً عن الغذاء الطبيعي ولمدة 90 يوماً. وقد أظهرت النتائج للتغيرات النسيجية المرضية أن المجموعة التي غذيت على غذاء غني بالكوليستيرول ch تبدي آفة تصلب عصيدي متنامية حتى نهاية التجربة وتليفاً في نسيج الكبد وتكاثر القنوات الصفراوية. صبغة فان كوسن أظهرت مادة الألياف الغروي (الكولاجين) في أنسجة الكبد المتأثرة بالمرض. أما الصبغة PAS فقد أظهرت تراكم مادة الميكوبوليسكرايد في أنسجة الكبد التي تأثرت بالمرض وعدم وجودها في الأنسجة التي لم تتأثر. ومن خلال هذه الدراسة تبين أن للمستخلص الزيتي للحبة السوداء وما فيه من مواد فعالة تأثيراً مخفضاً لكوليستيرول مصل الدم في الأرانب وله دور في منع حدوث التصلب العصيدي والتغيرات النسيجية التي يحدثها في الأنسجة.

## Introduction

Many of researches and studies on the seeds of *Nigella* revealed its role in treating many medical problems such as hypertension (1). Al-Awadi, et al, were study effect of the several Plant Extract including the black bean on the level of glucose in diabetes disease, particularly cases of diabetes are independent on insulin (2). Worthen, et al, were study the ability of black seed oil in the inhibition of Chemical carcinogenesis (3). Chakravarty (1993) was studied the influence of *Nigella* on the sensitivity of the chest through its effect on mast cells saturated with histamine, due to presence of (Polythymoquinone) in the structure of the *nigella*, this material was prevent the release of histamine from mast cell (4). Akhtar and Riffat were capable to give, black seed powder and oil extract black seeds doses ranging from (20- 40 mg\ kg of Bw) to treated the children infected with tapeworm eggs without any side effects (5). In the other hand some of studies improved effect of black seed oil in inhibition the growth of many kinds of bacteria. Hanafy and Hatem were found the extract of black seed has effect inhibition each of the bacteria: *Escherichia coli*, *Pseudomonas aeruginosa*, *Staphylococcus aureus* also found that the effective in the treatment of topical inflammation caused by bacteria, *Staph. aureus* in the skin of mice (6). In addition has effect on viral and fungal infection(7).

## Materials and Methods

Fifty of New Zealand white color male rabbits, has been selected randomly and were housed animals in cages clean and sterile at a rate of five per cage. Rabbits were left four weeks for adaptation to the conditions of the experiment. *Nigella sativa* seeds were isolated and cleaned from dirty, and was squeezed by Automated Hydraulic press, and use a pressure of 400 Bar to get the oil extract. Dose used 500 mg of oil extract\ Kg of BW daily. Dissolved crystals of cholesterol in sufficient quantity of ether and poured over the grains of feed and regularly at a rate of 1 g of cholesterol per one kilogram of feed, and then let these pieces of food to dry well in the open air. Then used as food for some groups, rabbits in the experiment.

### - Experimental design:

Rabbits were selected at randomly and divided in five groups, each group consisting of ten animals:

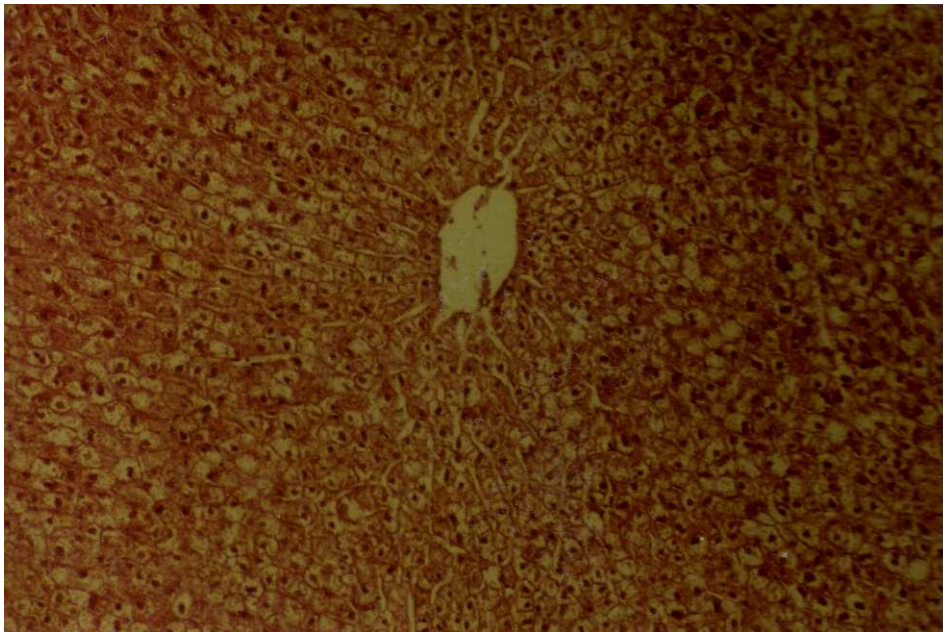
1. Control group (C) were fed a normal diet for 90 days, with the solution dosage normal saline 0.5ml\ kg BW of each animal by stomach tube.
2. Group (Ch) which given normal diet plus a cholesterol as 1% per day for 90 days.
3. Group (NCh) which fed extract oil of the black seed and a dose of 500 mg per day for each animal with fed on a diet rich in 1% cholesterol for a period of 90 days by using a stomach tube.
4. Group (ChN) which fed with extract of black seed oil at for 30 days, and then fed of food high in cholesterol by 1% for 60 days.

5. Group (N) which deal with black seed oil extract at a dose of 500mg kg\ BW each animal by using a stomach tube for a period of 90 days.

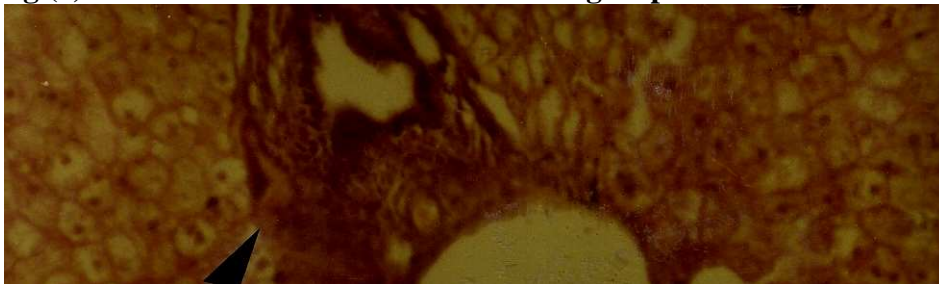
The animals were dissected and liver tissue was taken a small thickness of 1 cm per piece. The sample were fixed in formalin 10% for histopathological study and used Haematoxylin and Eosin as routine stains and Periodic acid schiff and Van Gieson's stain as special stain.(8)

### Results

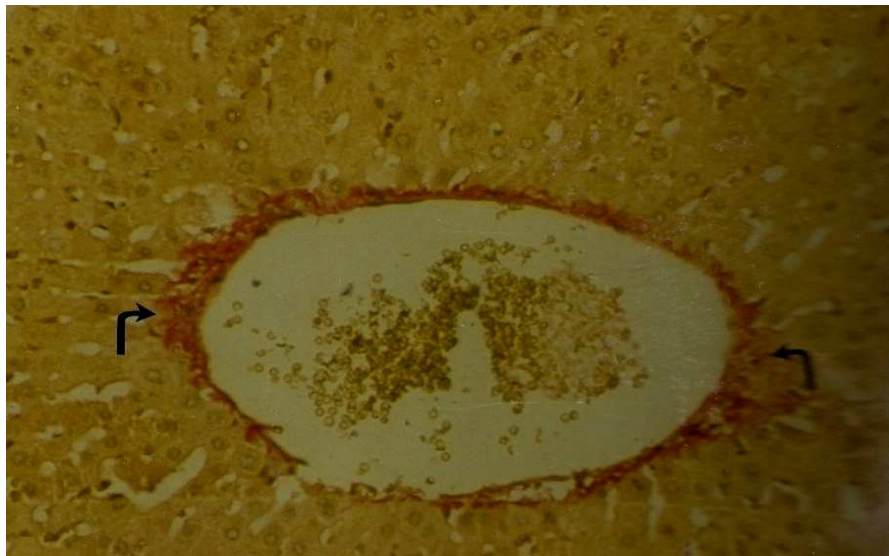
The results were showed normal appearance of liver tissue in control group Fig(1), while the results were showed fibrosis around the portal vein with the proliferation of fibroblast early with the proliferation of fiber tissue along of the bile ducts around the portal vein to the liver at the first month in the ch group Fig. (2). The group chn has been observed proliferation around the portal vein to a lesser extent from the group ch and the absence of proliferation of the bile duct on the portal vein and this illustrated character, the Van Gieson's stain to detect the presence of collagen fiber Fig. (3), while there is no histological changes recorded in groups nch and n during the first month of the experiment to other groups. During the second month group ch showed change evident in the liver tissue where extended fibrosis around the portal vein and become an extensive septal fibrosis and proliferation of bile ducts with Infiltration of a large number of inflammatory cells in the area of fibrosis around the portal vein and bile ducts has shown, the Van Gieson's stain was revealed the collagen fibers on the portal vein and give a dark red color of the Fig. (4). The PAS stain showed deposits of mucopolysuccarid in the liver tissue Fig (5). The group chn the tissue changes did not appear different than it is in the first month which presence of fibrosis around the portal vein and very small amount of fibroblast and collagen. The group Nch there has been no change in the liver tissue. The group N did not notice any change in the liver tissue in the third month while the ch group has shown an apparent change in liver tissue were observed on the presence of cirrhosis of the liver and portal vein extension forming barriers and the proliferation of bile ducts in more. PAS dye showed a positive response as it was observed depositing large amounts of material mucopolysuccarid in liver tissue.



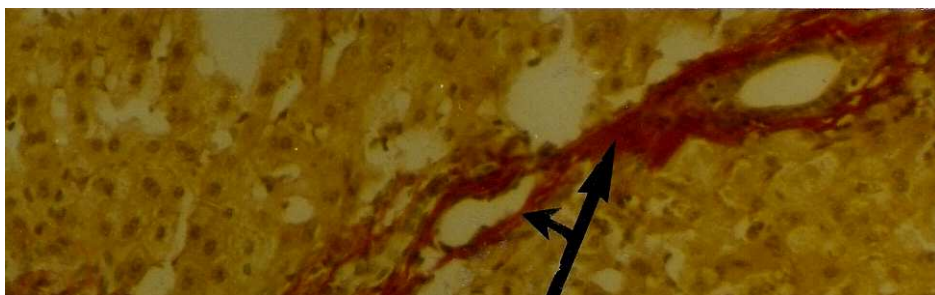
**Fig (1) Liver with normal tissue as control group H & E stain. 250x**



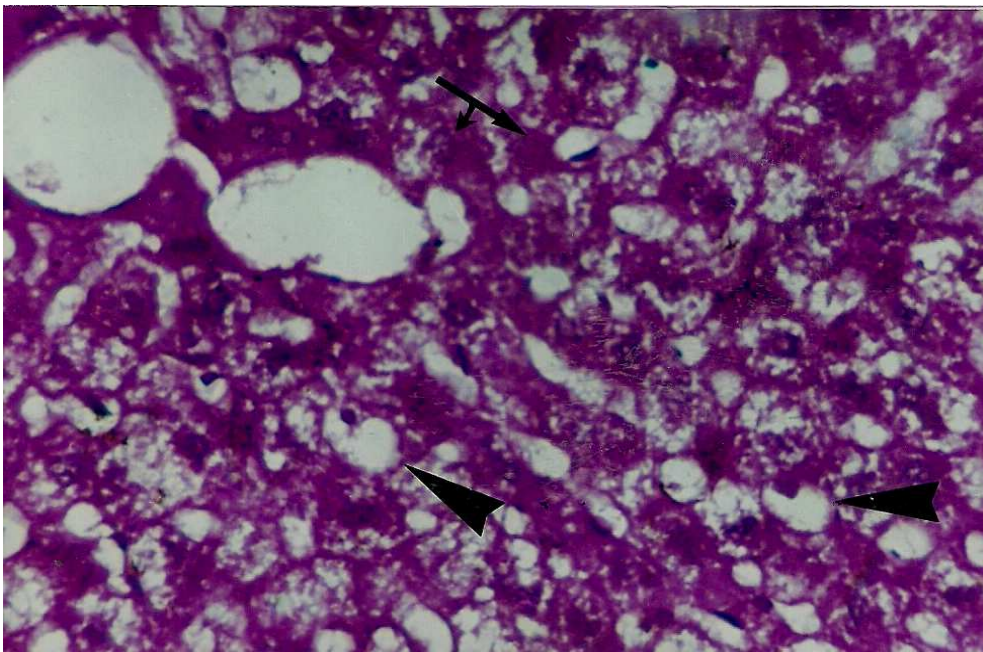
**Fig (2) liver: Moderate proliferation of fibrous connective tissue in the portal area in ch group at first month (H&E). 400x**



**Fig(3) Liver tissue the presence of collagen fiber around the portal vein stained with red colour in chn group at second month (Van Gieson's stain).400x**



**Fig (4) Liver tissue collagen fibers on the hepatic portal vein and bile ductile extended partitions composed of red color in group ch at third month. (VanGieson's stain). 400x**



**Fig (5) The PAS stain showed deposits of mucopolysuccarid deposited with purple and heavily in the liver tissue of ch group at third month. 400x**

## **Discussion**

The results showed the presence of cirrhosis of the liver tissue around the portal vein and found fibroblast early in the group ch at day 30 of start feeding, and extended fibrosis forming barriers in day 60 to start feeding with the increase in collagen fiber and mucopolysuccarid This is due to the fatty food, which was given to animals. (9, 10) Show that the animals which dependent on fatty food were undergo to fibrosis in liver because of stimulate increasing of fibroblast cells and fiber component (8,9). At day 90 of experiment was revealed increased in size of the fibrosis and extended between the lobes of the liver constituting barriers, and become extended from portal vein to others, proliferated bile ducts are more and accumulate of mucopolysuccarid with the increase amount of collagen fiber due to increase ratio of lipid in the diet that agree with James, et al., (11) were explained that it was due to the deposition of fat in the tissues of rabbits, when given a diet high in cholesterol for a period of 12 weeks. (10) Also show cirrhosis and thickening of portal vein at the 30 day of experiment while this changes become decrease gradually at 60 and 90 days of experiment for animals deal with black seed, the increase in the level of cholesterol led to the emergence of fibrosis in liver tissue and this is agree with what is found (12) when studied on rabbits that the cholesterol and their saturated esters were act as induced factors for fibrosis and cirrhosis (11). The low level of cholesterol in the blood serum at 90 day of start feeding led to the disappearance of fibrosis which was due to the derivatives of sterols which found in the extracted oil of the black seed (12) and its special role in fat metabolism and balanced in the body by inhibiting absorption of cholesterol, which increases the secretion of bile salts and stop the esters of cholesterol and isolate the cholesterol subject almost collagen to bile salts and prevents its absorption in the intestines, as well as prevent making of triglyceride in the liver tissue, which reduces the synthesis of lipoproteins and low density is extremely in the serum, as well as reduces cholesterol in the liver, which helps to balance the cholesterol in the liver tissue. The group Nch that dosage extract of black seed for 90 days were fed diet rich cholesterol as of today, 30 for 60 days, the results show the absence of any histopathological changes in spite of giving the fatty food for 60 days. This may be due to that been eliminated in the first month of giving extract of the black seed was decrease formation and accumulation of cholesterol in the tissue by stimulate to increase formation of bile acid and lipase enzyme which increases the solubility of cholesterol and absorption through the intestine, and the last leads to inhibition of feed back mechanism of the manufacture of cholesterol in the liver, as well as it contains antioxidants that prevent oxidation of fats, particularly lipoprotein and low density and preventing deposition in tissues as well as the effort to prevent oxidation of the work of destroying tissue by preventing the oxidation. All these factors have a role in reducing the level of cholesterol in the blood serum in spite of giving the animals a diet high in cholesterol. Moreover extract oil of the black seed contains 58.1% fatty acids and polyunsaturated, recent studies that have proven effective role as it works to reduce the level of serum cholesterol. As well as containing soluble fiber very important, studies have shown that the fibers dissolved important role in reducing the level of cholesterol through the conversion of cholesterol to acid yellow and are also influenced by soluble fiber on the absorption of cholesterol and inhibit the manufacture in the liver (13). The group N, which dosage extract oil of black seeds not show any histological changes during the experiment periods.

## References

1. Zaoui, A.; Cherrah, Y.; Lacaille, D. M. A.; Settaf, A.; Amoarouch, A. & Hassar, M. (2000). Diuretic and hypotensive effects of *Nigella satvia* on the spontaneously. *Therapie.*, 55(3):370-382.
2. Al-Awadi, F. H. & Shamot, U. (1991). The effect of plant mixture extract on liver Gluconeogenesis in streptozotocin induce diabetic rats (Liver disease). *Diabetes Res.*, 18(4):163-168.
3. Worthen, D. R.; Ghosheh, O. A. & Crooks, P. A. (1998). The in vitro antitumor activity of some crude and purified component of black seed, *Nigella satvia*. *Anticancer Res.*, 18(3A):1527-1532.
4. Chakravarty, N. (1993). Inhibition of histamine release from mast cell by Nigellone. *Ann. Allergy.*, 70(3):237-242.
5. Akhtar, M. S. & Riffat, S. (1991). Field trial saussurea lappa roots against nematods and *Nigella satvia* against cestodes in children. *JPMA. J. Pak. Med. Assoc.*, 41(8):185-187.
6. Hanafy, M. S. & Hatem, M. E. (1991). Studies on the antimicrobial activity of *Nigella sativa* seed (Black cumin). *J.P.M.A.J. Pak Med. Assoc.*, 41(8):185-187.
7. Abdulkader, H. A.; Seddek, S. R. & El-Shanawany, A. A. (1995). In vitro study of the effect of some medical plants on the growth of some dermatophytes. *Assiut Vet. Med. J.*, 34(67):36-42.
8. Linda, L. V. (1985). *Laboratory Manual of histochemistry*. Reven Press, New York.
9. Vesselinovitch, D.; Getz, G. S.; Hughes, R. H. & Wissler, R. W. (1974). Atherosclerosis in Rhesus monkey feed three food fats. *Atherosclerosis*, 20:303.
10. Wissler, R. W.; Vesselinovich, D.; Borenztajn, J.; Schaffner, T. & Hughes, R. (1976). Effect of various dietary responses on progression of atherosclerosis in Rhesus monkey. *Fed. Proc.*, 35:625.
11. James, B. A.; Richard, L. H.; Karen, K. B. & Larry, L. S. (1989). Cholesterol-fed heterozygous Watanabe heritable hyperlipidemic rabbits: a new model for atherosclerosis. *Atherosclerosis*, 78:123-136.
12. Abdulla, Y. H.; Adams, C. W. M. & Morgan, R. S. (1967). Connective tissue reaction of purified sterols, esterol, estres, Phosphogylearides and free fatty acid. *J. Path. Bact.*, 94:63.
13. Salama, R. B. (1973). Sterols in the seed oil of *Nigella sativa*. *Plant Medica.*, 24:375-377.
14. James, W.; Anderson, L. D.; Allgood, A. L.; Linda, A. A.; George, R. J.; David, A. H. & Jorge, G. M. (2000). Cholesterol lowering effect of psyllium intake adjunctive to dite therapy in men and women with hypercholesterolemia. *Am. J. Clin. Nutr.*, 71:472-479.